PLASTERING AND SPLINTING

Matt Woronczak

the.emergencyphysio.com

RESOURCES

- The.emergencyphysio.com
- https://www.bsnmedical.com/products/orthopaedics/category-product-search-o/fracture-management/synthetic-splinting/ortho-glassr-dynacastr-prelude.html
- https://www.rch.org.au/clinicalguide/guideline_index/Fracture_casting_videos/
- https://www.rch.org.au/clinicalguide/guideline_index/fractures/Radialulna_shaft_diaphysis_fractures_Emergency_Department/

OVERVIEW

- Splinting serves to immobilise joints to:
  - **Provide pain relief**
  - Limit movement and permit more rapid healing (not just fractures)
  - Maintain anatomical alignment

- Splinting can be done:
  - Immediately on initial assessment of a patient (prior to imaging)
  - For definitive treatment

SPLINTING INJURIES

- The Ancient Egyptians used wooden splints wrapped in linen and stiff bandages

- Other cultures used a variety of techniques to stiffen bandages, including using resins, starches and other products

- As these often took days to dry, other techniques were developed including methods similar to papier-mâché (cardboard, bandages soaked in starch / dextrin solutions)

SPLINTING INJURIES

- The use of bandages impregnated with plaster have been used since the 1850s.

- More recently, synthetic products have been developed as alternatives to plaster, however plaster is still used frequently (especially in public health)

MODERN SPLINTING MATERIALS

- PLASTER OF PARIS
  - Pros
    - Cheap
    - Diverse range of applications
    - Easy to mould / alter
    - Takes 2-3 days to fully dry
  - Cons
    - Can be messy
    - Will weaken if re-wet (but will re-set again)
    - Comparatively heavy
    - Takes 2-3 days to fully dry

MODERN SPLINTING MATERIALS

- SYNTHETIC / FIBREGLASS
  - Pros
    - Lighter yet more rigid / durable than POP
    - Does not weaken if re-wet (however padding underneath is still not waterproof, so still shouldn't get cast wet)
    - Lower curing temperature – not enough to cause thermal damage (regardless of water temp)
  - Cons
    - More expensive
    - More difficult to mould / alter / remove
    - As product is harder and the ends sharper, can cause problems with pressure areas
    - Reaches maximum hardness rapidly (no give for developing swelling)

MODERN SPLINTING MATERIALS

- THERMOPLASTIC
  - Pros
    - More breathable than most other materials
    - Diverse range of applications
    - Once you know how, easy to mould / alter
  - Cons
    - Higher temperatures required to use
    - Usually need frying pan, heat gun to work with
    - Need more skilled users
    - Not particularly practical for ED
    - Bigger splints can be expensive

MODERN SPLINTING MATERIALS

- ALUMINIUM SPLINT
  - Pros
    - Quick application
    - Little skill or knowledge required
  - Cons
    - Not particularly well contoured to individual
    - Bulky
    - Hard to cut

MODERN SPLINTING MATERIALS

- PRE-FABRICATED SPLINTS
  - Pros
    - Quick application
    - Little skill or knowledge required
  - Cons
    - Not particularly well contoured to individual
    - Can be more expensive than custom splint

PLASTER OF PARIS

PLASTER OF PARIS

- Plaster of Paris is created when gypsum (a soft mineral comprised of calcium sulfate dihydrate - $CaSO_4 \cdot 2H_2O$) is heated to 150˚C, where the mineral partially dehydrates, with 75% of the water content escaping as water vapor.

- Plaster of Paris is otherwise known by its chemical name calcium sulfate hemihydrate and has the chemical formula $CaSO4 \cdot ½H2O$

PLASTER OF PARIS

- It is colloquially called Plaster of Paris for the significant deposits of gypsum found around Paris



PLASTER OF PARIS

- When water is re-added to Plaster of Paris, it resets itself as a gypsum crystal lattice and undergoes an exothermic reaction, which creates heat

$$2\,(CaSO_4 \cdot \tfrac{1}{2}\,H_2O) + 3\,H_2O \rightarrow 2\,(CaSO_4 . 2H_2O) + \underline{\text{Heat}}$$

PLASTER OF PARIS

- The warmer the water, the quicker the reaction, but also the more heat is generated (with warm/hot water, this can be as high as 100C!)
  - Halanski et al (2007)
    - Water temperature over 24°C can cause thermal injury (tap water temperature varies in Melbourne from 15-22°C depending on the season and location)
    - Curing temperature is higher with more layers
      - Do not fold excess plaster back – cut it off
    - If using fibreglass over plaster, wait until plaster has cured before applying fibreglass
    - Avoid putting curing cast on a pillow

PLASTER OF PARIS

- POP generally becomes reasonably rigid after 10-15 minutes, however it takes approximately 72 hours before the cast is fully dry.

CIRCUMFERENTIAL vs SLABS

- Circumferential plasters are generally used for more substantial fractures where more support is warranted

- Slabs are sheets of plaster applied to one side of a limb and are generally used for less substantial injuries, for injuries where substantial swelling is expected, or as an interim measure for injuries requiring surgery

PLASTERING BASICS

- http://the.emergencyphysio.com/Files/Videos/Casting/plasteringbasics.mp4

NEUROVASCULAR ASSESMENT

- Colour
- Movement
- Warmth
- Sensation
- Capillary refill
  - < 2 seconds
- Pulses

NEUROVASCULAR ASSESMENT

Adapted from[2]

Assessment of Neurological Status in Upper Limb Injuries

Nerve	Median	Radial	Ulnar	AIN (Anterior Interosseous)
Paediatric fractures associated with neurological deficit[1]:	Supracondylar (4%) Radius & Ulna	Supracondylar (4-6%) Humeral Shaft	Supracondylar (2%) Radius & Ulna	Supracondylar (5%) Radius & Ulna (Diaphyseal)
Motor Assessment	 Finger flexion	 Extension of wrist & MCP joint	 Small muscles of hand (finger abduction & adduction)	 Thumb flexion at IP joint & flexion of index finger at DIP joint
Sensory Assessment				N/A

Documentation of Neurological Status should ALWAYS include which nerves have been examined.

eg. **Neurovascularly Intact** (*Radial* ✓ *Ulnar* ✓ *Median* ✓ *AIN* ✓)

1. Babal et al. Nerve Injuries Associated with Paediatric Supracondylar Humeral Fractures: A Meta-Analysis. Journal of Paediatric Orthopaedics 2010
2. Davidson AW. Rock-Paper-Scissors. Injury. International Journal of Care of Injured. 2003; 34:61-63

Review date: Dec2015

WHA IS WRONG IN THIS X-RAY?

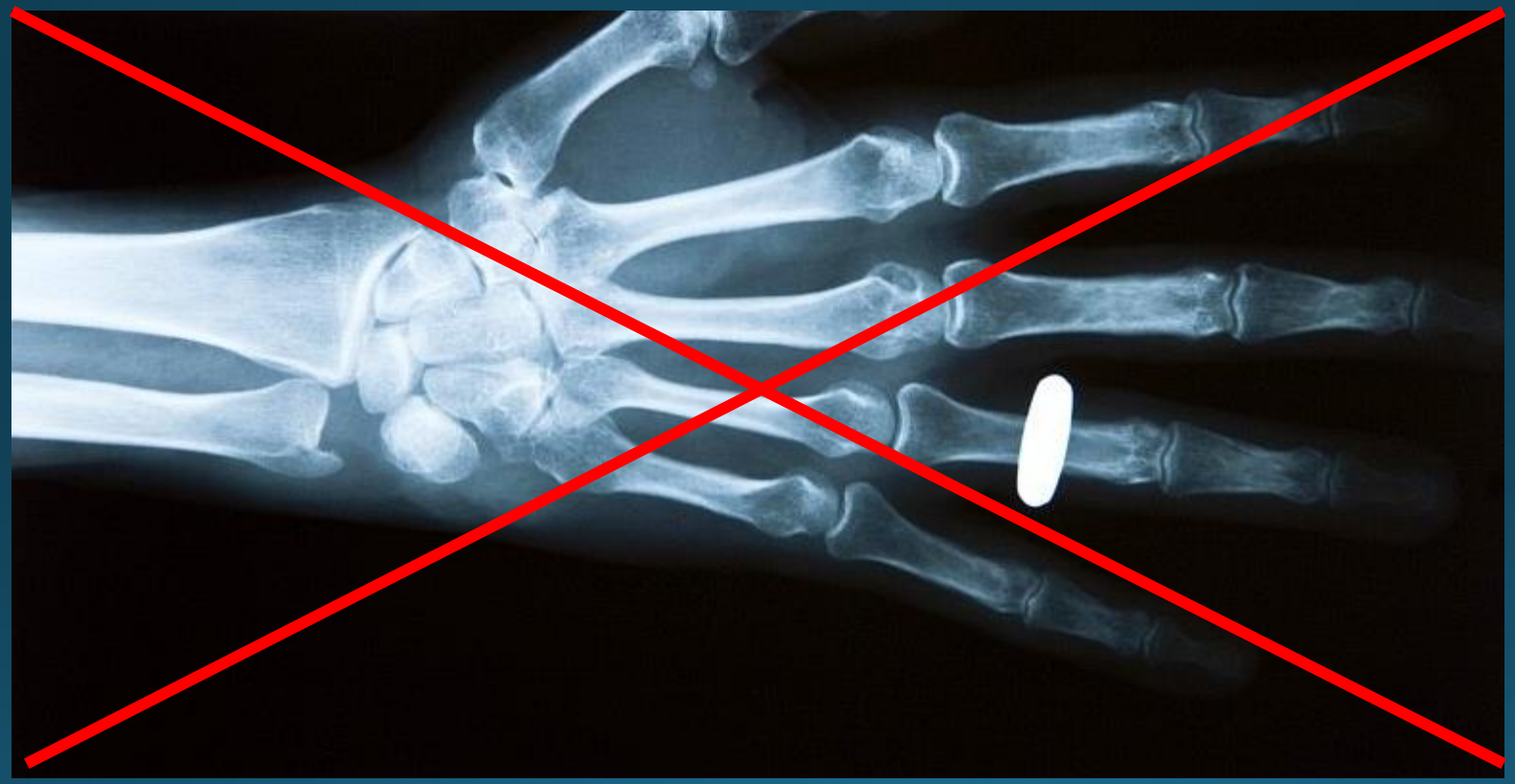

REMOVING A RING

REMOVING A RING

REMOVING A RING

https://www.youtube.com/watch?v=DxoAbK5Pc6w

REMOVING A RING

REMOVING A RING

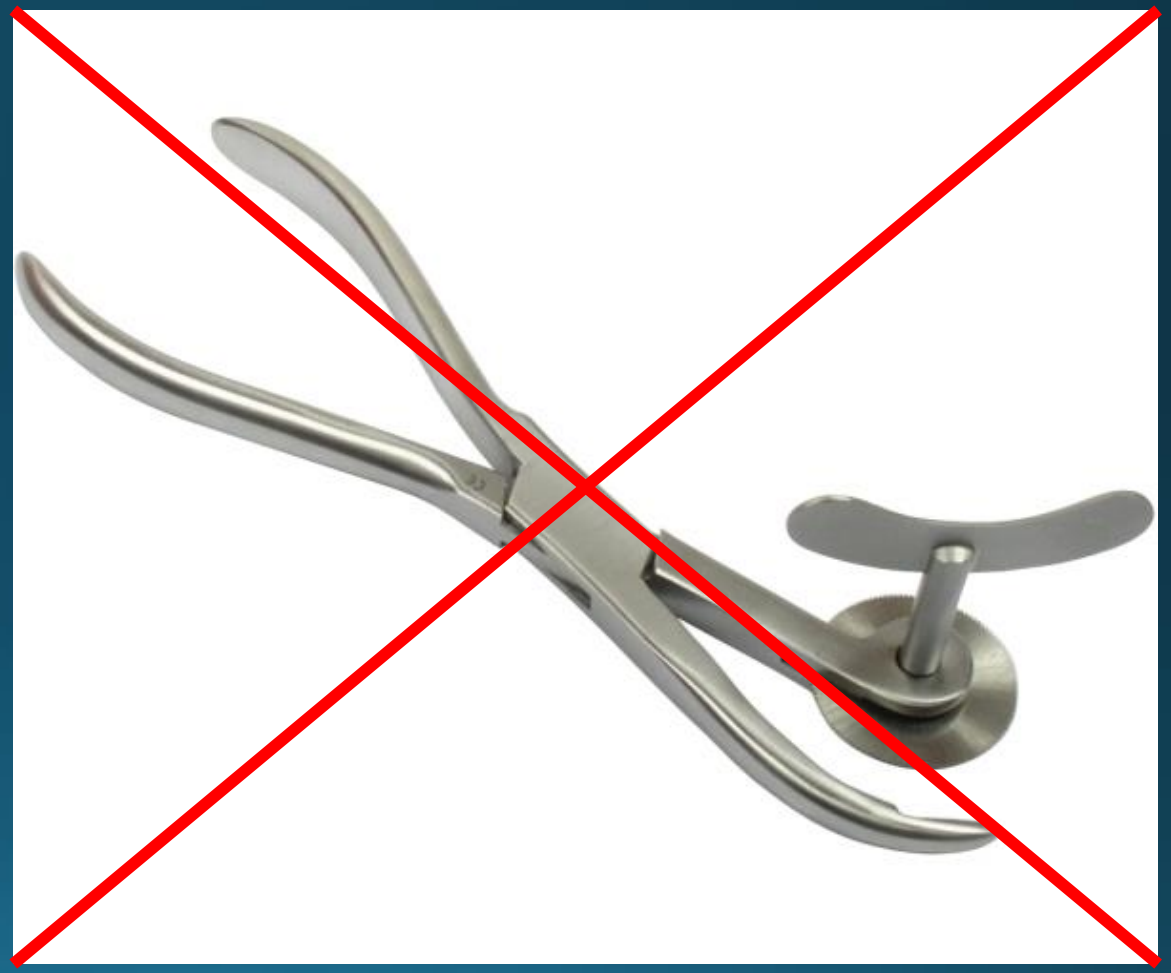

REMOVING A RING

PLASTER CARE

- Elevate as much as possible for at least the first few days or until the substantial symptoms subside
  - Above the level of the heart
- Keep cast / splint dry
  - Cover with a plastic bag for showering
  - If accidentally get a little bit wet = leave to dry by itself
    - When plaster gets wet again, it will cure again and release heat
    - If you use a hairdryer or put it in front of the heater, you can burn the skin
  - If gets really wet such that water is held against the skin, needs to be changed
- Avoid putting weight through affected limb
- Do not drive with a cast or rigid splint on
  - Insurance will not cover you
  - It may also be illegal
- Do not stick anything down to cast to scratch
  - It will bunch up the padding and expose skin to plaster = pressure areas

PLASTER CARE

- Return to the ED if, DESPITE ELEVATION:
  - Fingers are freezing cold, white or blue
  - Unable to feel or move fingers
  - Severe unrelenting pain not aided by taking simple analgesia

SCV ED plaster care handout from https://www.bettersafercare.vic.gov.au/sites/default/files/2019-07/Fractures%20and%20plaster%20care.pdf

SCV Safer Care Victoria / Emergency Care Clinical Network

We're #withconsumers CHF Consumers Health Forum of Australia

Fractures and plaster care

WHAT IS A FRACTURE?

A fracture is a medical term for a broken bone. Bones break when too much force is exerted against them, often during a fall or common activities such as sport. Given time and the right care, the bone heals itself.

TREATMENT

You may have had x-rays in the emergency department or urgent care centre to check for a fracture. In most instances, a cast will be applied to hold the broken bone(s) in place while the bone heals. It is more common to have a half cast than a full cast. Other fractures may be managed with slings or splints.

WHAT TO EXPECT

- Fractures can be painful. The pain can be extreme at the beginning, but it will ease once the plaster or splint is on and the fractured limb is supported and rested. The pain will settle even further over the next few days to weeks.
- Simple pain medications such as paracetamol are often needed. Take them as needed and follow the instructions on the packet. Your doctor may prescribe stronger pain relief. Some medications may make you drowsy; if so, do not drive or operate machinery. Your doctor, nurse or pharmacist should also provide you with some specific information about pain management.
- A cast may be itchy for a few days, but this should ease.
- After the cast is removed, there may be some stiffness and weakness in the limb. This should improve as you go about your normal activities.
- Sometimes physiotherapy is needed to help recovery.
- The bone will continue to recover, even after the cast or splint is removed. Take extra care and precautions to not reinjure the recovering bone, especially for the first six weeks.
- You may feel a lump at the site of the fracture. This is the new bone, which will eventually take on the shape of your original bone.

CARING FOR THE FRACTURE

The cast, sling or splint will support and protect the bone while the fracture heals. It can sometimes cause problems with blood flow, especially in the first couple of days. The following advice may help to avoid problems.

- Frequently move or wiggle the fingers (in the case of an upper limb plaster) or toes (for a lower limb plaster).
- Keep the plaster raised (ideally above your heart) to prevent swelling, especially for the first 48 hours (for example, use a sling to keep an arm raised or place pillows under your leg when resting).
- It is important for your recovery that you keep the cast in good condition.

CARING FOR THE PLASTER OR FIBREGLASS CAST

It is important that you look after your cast.

- Rest for a couple of days after the cast is applied to allow it to set completely.
- Keep the cast dry. When having a shower or bath, put a plastic bag over the plaster and seal it with a rubber band. Try to keep the limb away from water, to prevent any leaking in. Keep the plaster out of the rain.

COMMON UPPER LIMB INJURIES

- COLLES FRACTURE

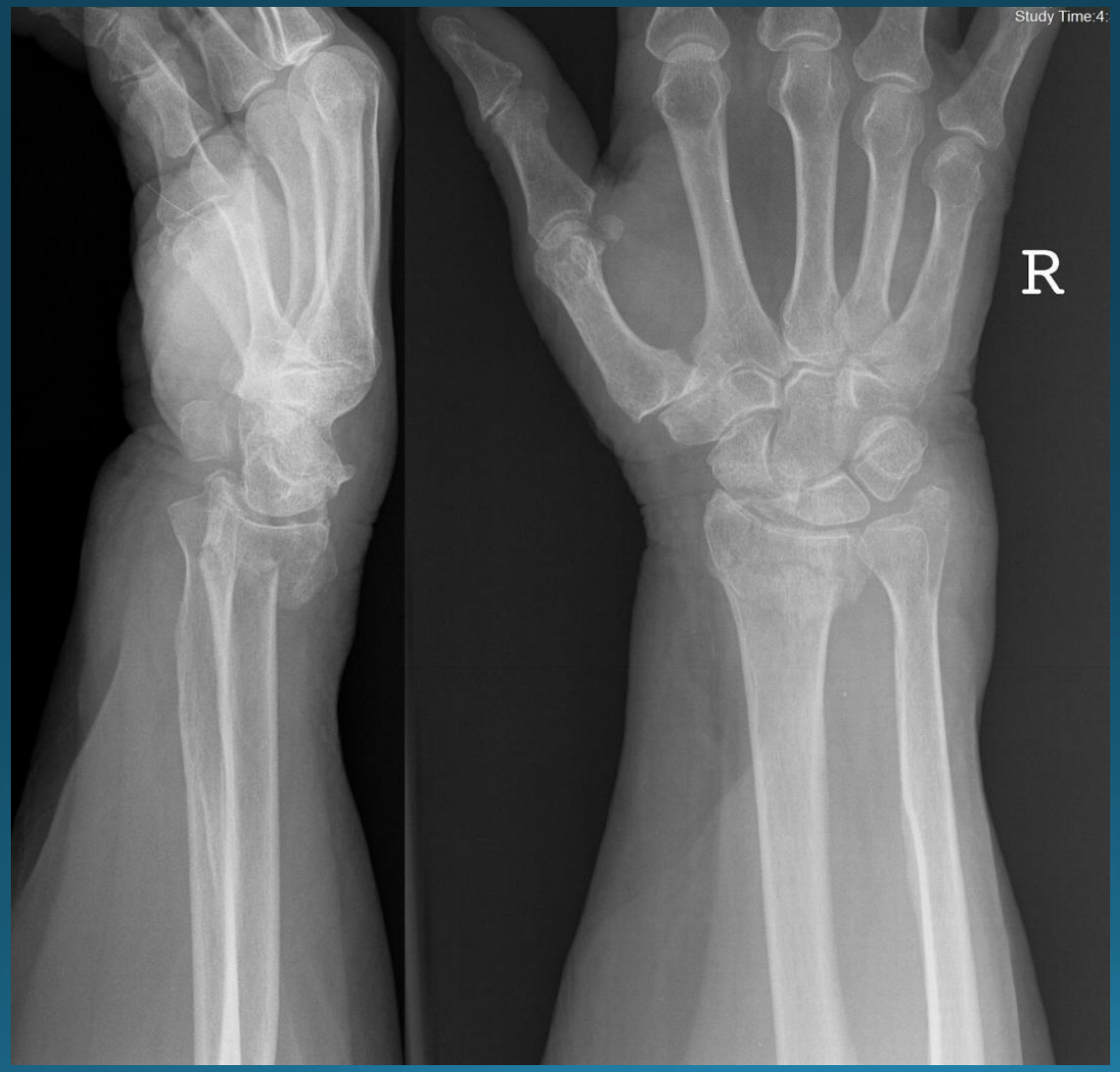

BELOW ELBOW POP

- A circumferential plaster used where more support is warranted eg more substantial fractures or post reduction of a wrist fracture

- Proximal Landmark
  - Just distal to the elbow crease, allowing free elbow flexion

- Distal Landmark
  - Extends to the distal palmar crease

- Position of Immobilised Joints
  - In a regular BEPOP, the wrist is held in 30 degrees of extension and the thumb is not included
  - A Colles POP is a BEPOP with the wrist flexed 30 degrees and deviated in an ulnar (medial) direction

BELOW ELBOW POP

http://the.emergencyphysio.com/Files/Videos/Casting/bepop.mp4

THREE POINT MOULDING

THREE POINT MOULDING

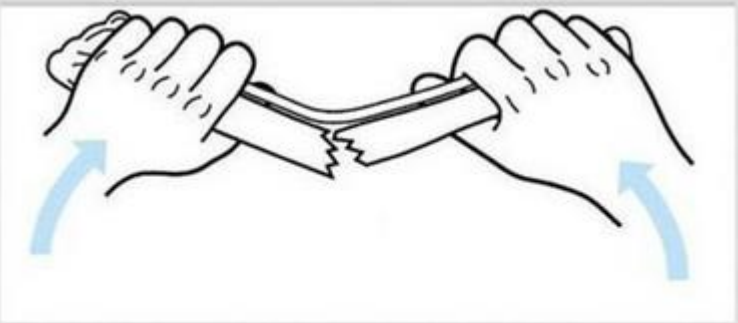

Figure from Chapman' s Orthopaedic Surgery 3rd Ed. (Redrawn from Charnley J. The Closed Treatment of Common Fractures, 3rd ed. Baltimore: Williams & Wilkins, 1963.)

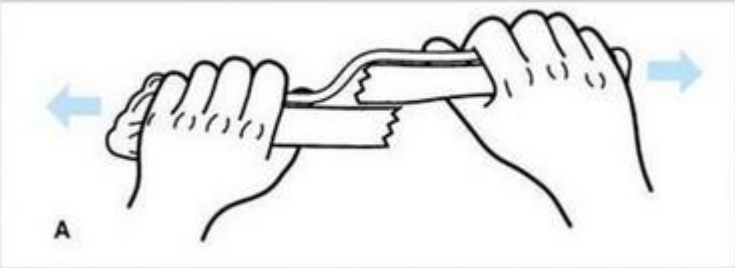

Figure from Chapman' s Orthopaedic Surgery 3rd Ed. (Redrawn from Charnley J. The Closed Treatment of Common Fractures, 3rd ed. Baltimore: Williams & Wilkins, 1963.)

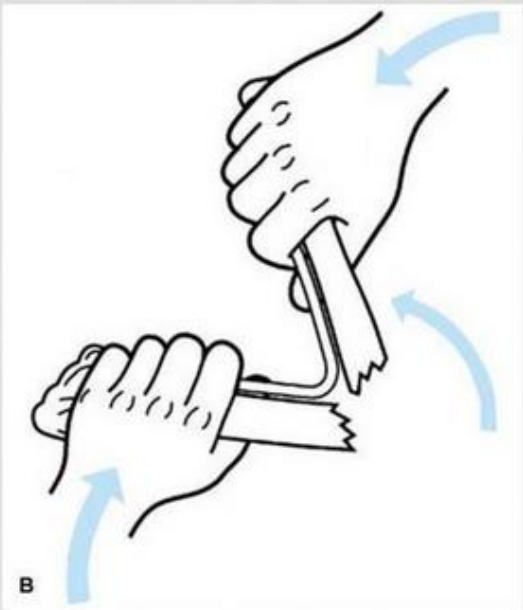

Figure from Chapman' s Orthopaedic Surgery 3rd Ed. (Redrawn from Charnley J. The Closed Treatment of Common Fractures, 3rd ed. Baltimore: Williams & Wilkins, 1963.)

ABOVE ELBOW POP

- Extending the cast to the upper arm is necessary for midshaft or proximal forearm fractures
- They commence just distal to the deltoid insertion and finish as per a below elbow cast. Generally the elbow is positioned in 90 degrees flexion and in mid prone
- Acute elbow fractures should never be managed with a circumferential cast due to the risk of compartment syndrome and neurovascular compromise
- These should only be performed by experienced clinicians

ABOVE ELBOW POP

= USUALLY ED

= (USUALLY)FOR ORTHO

= FOR ORTHO

= FOR ORTHO


L
JH


L
JH


L


L

Mid and distal third shaft fractures*

Age	<10 years	>10 years
Acceptable angulation	<15 degrees (up to 20 degrees <5 yrs old)	<10 degrees
	 AP view Lateral view	 AP view Lateral view

1/52 later

2/52 post injury

(approx. 15 degrees)

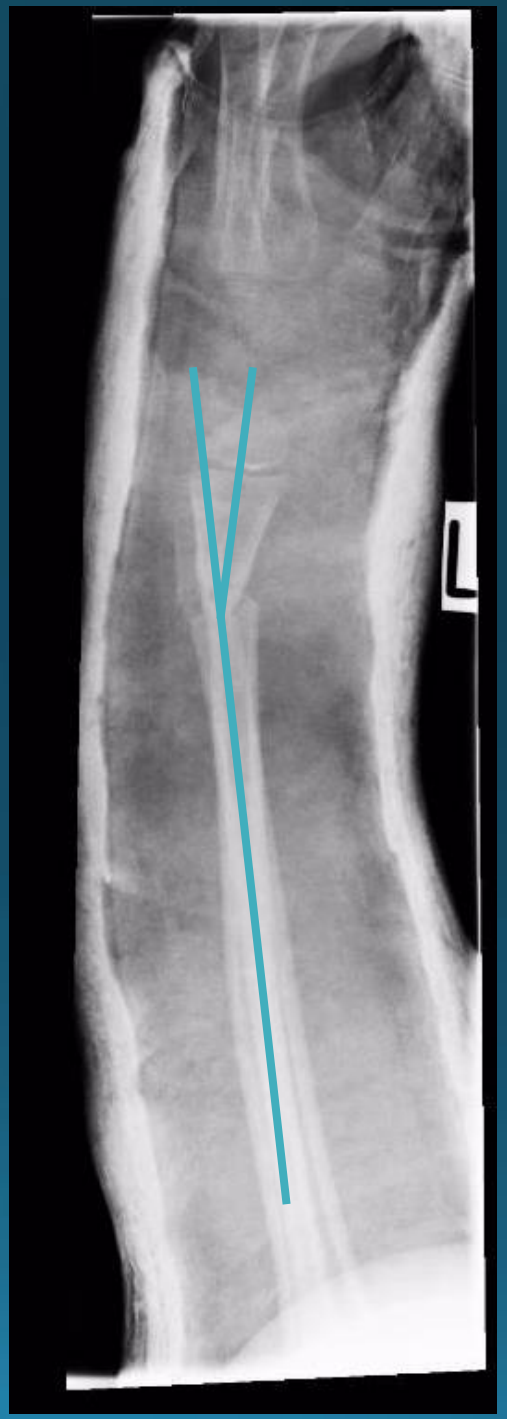

2/12 post injury (approx. 20 degrees)

1 year post injury

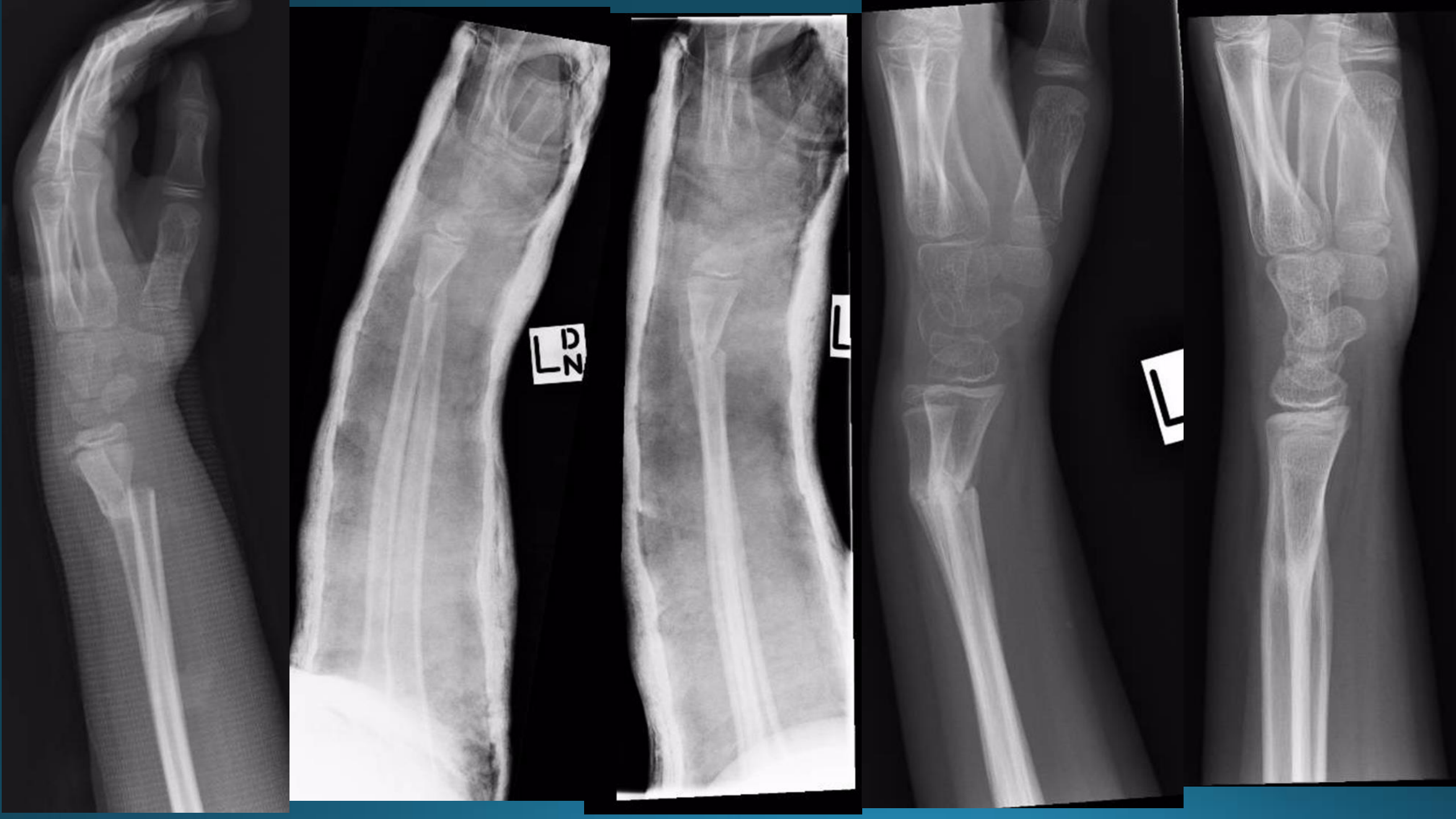
L
D
N
L
L

Buckle Fracture

VOLAR SLAB

- A slab used to immobilise the wrist for less significant injuries, or where substantial swelling is expected
- Proximal Landmark
  - Just distal to the elbow crease, allowing free elbow flexion
- Distal Landmark
  - Extends to the distal palmar crease
- Position of Immobilised Joints
  - The wrist is held in 30 degrees of extension

VOLAR SLAB

http://the.emergencyphysio.com/Files/Videos/Casting/dorsalvolarslabs.mp4

COMMON UPPER LIMB INJURIES

- METACARPAL FRACTURE

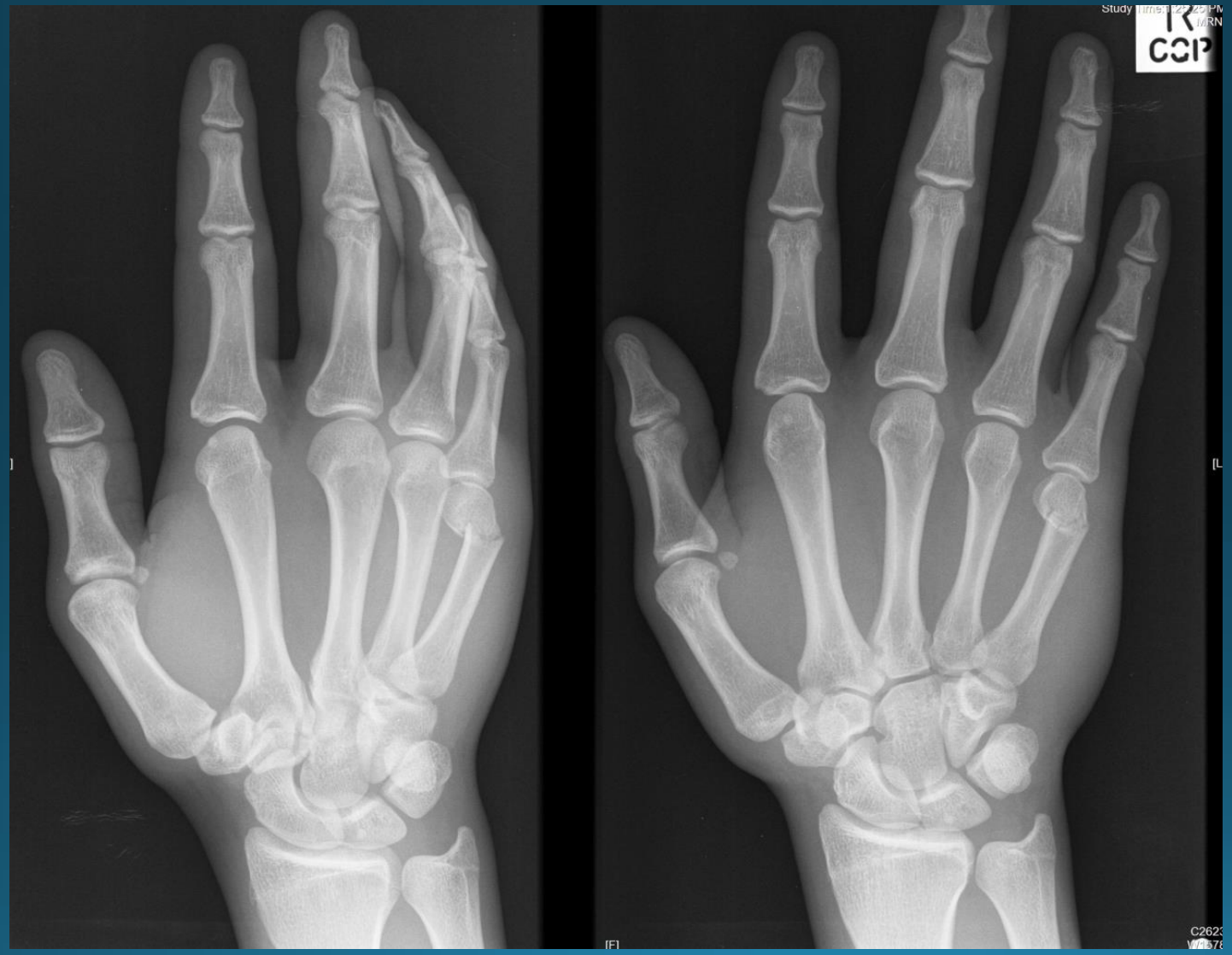

POSITION OF SAFE IMMOBILISATION (POSI) SPLINT

- A splint which rests on the anterior (volar) surface of the forearm and hand. It is used for metacarpal and proximal phalangeal fractures and other injuries about the hand

- Proximal Landmark
  - Commences approximately 3cm distal to the elbow crease (ensure does not impede elbow flexion)

- Distal Landmark
  - Extends distally to the tip of the longest finger

- Position of Immobilised Joints
  - The wrist is held in 30-40 degrees of extension, the metacarpals flexed to 90 degrees (or as far as possible) and the interphalangeal joints are kept fully extended (sock puppet position)

POSITION OF SAFE IMMOBILISATION SPLINT

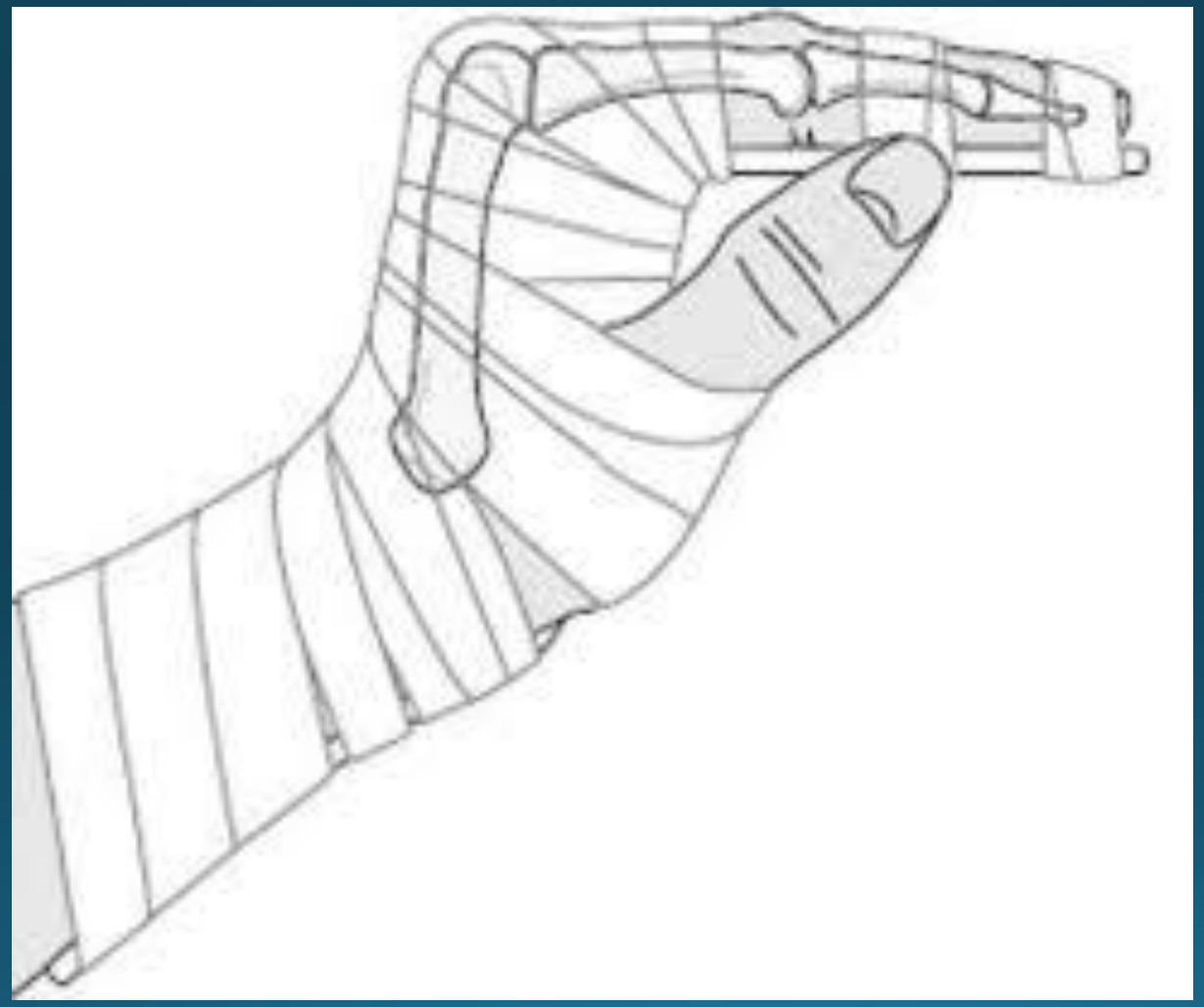

ULNAR GUTTER SPLINT

- A variation on the POSI splint where the splint is simply shifted to the ulnar side to only cover the 4th and 5th metacarpals and medial forearm
  - Used for 4th and 5th metarcarpal / proximal phalangeal injuries where swelling is not marked
- Proximal Landmark
  - Commences approximately 3cm distal to the elbow crease (ensure does not impede elbow flexion)
- Distal Landmark
  - Extends distally to the tip of the longest included finger
- Position of Immobilised Joints
  - The wrist is held in 30-40 degrees of extension, the metacarpals flexed to 90 degrees (or as far as possible) and the interphalangeal joints are kept fully extended (sock puppet position)

ULNAR GUTTER SPLINT

COMMON UPPER LIMB INJURIES

- RADIAL HEAD FRACTURE

COMMON UPPER LIMB INJURIES

- SUPRACONDYLAR FRACTURE

ABOVE-ELBOW BACKSLAB

- The above-elbow backslab immobilises the elbow and, depending on the injury, the wrist.

- Proximal Landmark
  - The splint should commence just below deltoid insertion

- Distal Landmark
  - For supracondylar / distal humeral fractures or elbow dislocations where the radio-ulnar joints are not affected, the splint does NOT need to include the wrist. The splint should end just proximal to the wrist crease
  - For radial head / neck fractures, the wrist should also be included (to restrict supination and pronation). In this case, the splint would extend to the distal palmar crease

- Position of Immobilised Joints
  - The splint holds the elbow into 90 degrees of flexion, the forearm into mid pronation (ie thumb up) and, if included, the wrist in 30 degrees of extension

ABOVE ELBOW BACKSLAB

COMMON UPPER LIMB INJURIES

- AVULSION FRACTURE

THUMB SPICA

- The Thumb Spica immobilises the thumb
- Proximal Landmark
  - The splint should commence approximately 1/3rd the way down the forearm from the elbow
- Distal Landmark
  - The spica should finish just proximal to the IP joint
- Position of Immobilised Joints
  - The splint holds the thumb in the OK position, with the wrist extended to 30 degrees, slight flexion at the MCP joint

THUMB SPICA

LOWER LIMB SPLINTS

COMMON LOWER LIMB INJURIES

- DISTAL FIBULAR FRACTURE

BELOW KNEE POP

- A circumferential plaster used for ankle fractures
- Proximal Landmark
  - Approximately 4cm distal to the fibular head (to avoid direct pressure on the common peroneal nerve and allow free knee movement)
- Distal Landmark
  - Just proximal to the MTP joints (to allow free MTP joint movement)
- Position of Immobilised Joints
  - The ankle is held in plantargrade (ie at 90 degrees)

BELOW KNEE POP

- http://the.emergencyphysio.com/Files/Videos/Casting/bkpop.mp4

COMMON LOWER LIMB INJURIES

- ACHILLES RUPTURE

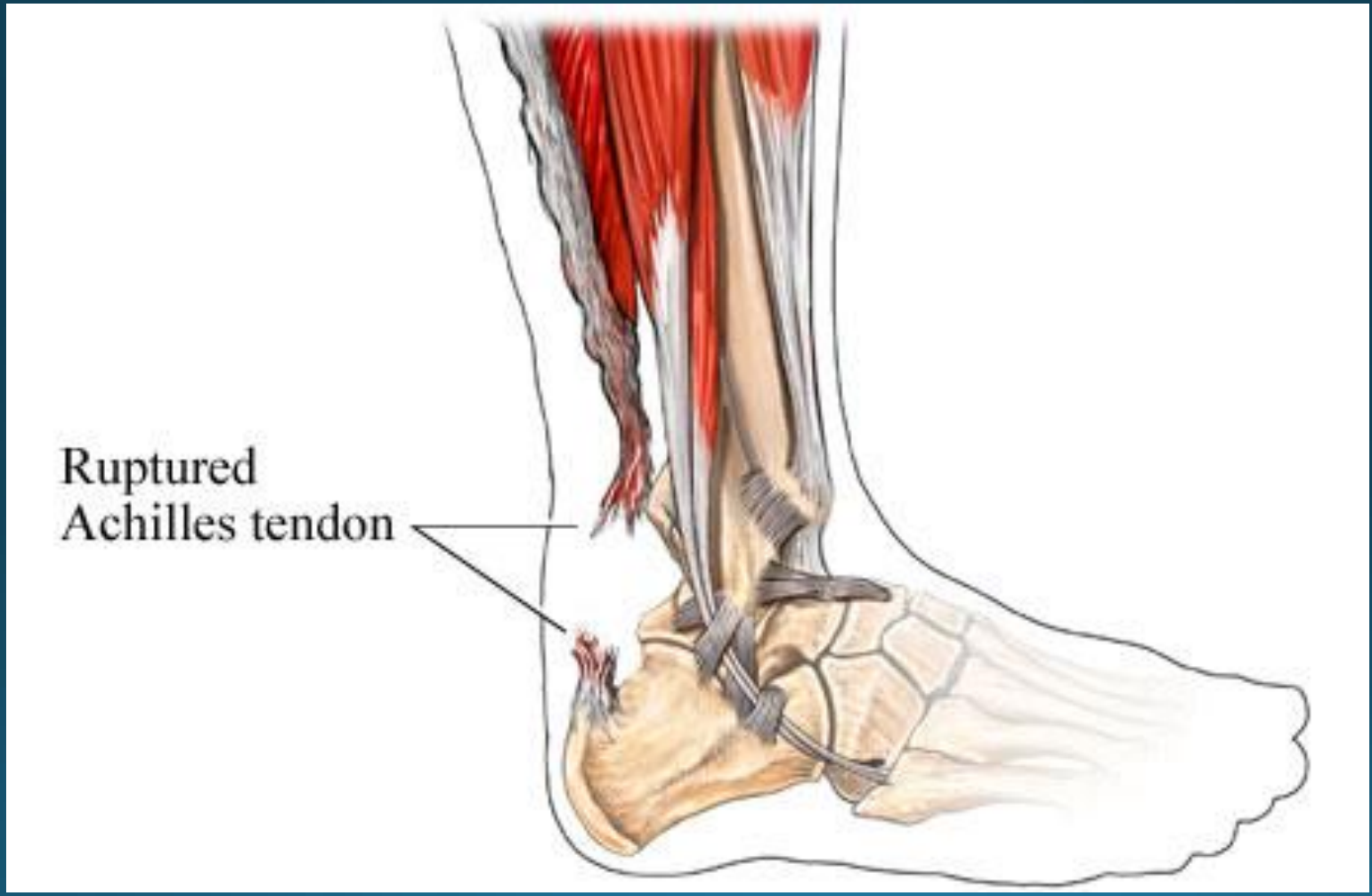

EQUINUS SPLINT

- A slab which is applied onto the anterior surface of the shin and foot used for achilles tendon injuries or lacerations on around the posterior distal leg

- Proximal Landmark
  - Approximately 4cm distal to the fibular head (to allow free knee movement)

- Distal Landmark
  - Just proximal to the MTP joints (to allow free MTP joint movement)

- Position of Immobilised Segments
  - The ankle is held in maximal plantarflexion (ie toes down)

EQUINUS SPLINT

- http://the.emergencyphysio.com/Files/Videos/Casting/equinus.mp4

COMMON LOWER LIMB INJURIES

- FIFTH METATARSAL FRACTURE

LOWER LIMB BACKSLAB

- A slab used to support foot and ankle injuries, which is applied to the posterior surface of the lower leg and foot

- Proximal Landmark
  - Approximately 4cm distal to the fibular head (to allow free knee movement)

- Distal Landmark
  - Just proximal to the MTP joints (to allow free MTP joint movement).

- Position of Immobilised Joints
  - The ankle is held in plantargrade (ie 90 degrees)

LOWER LIMB BACKSLAB

- http://the.emergencyphysio.com/Files/Videos/Casting/bkbackslab.mp4

LOWER LIMB U-SLAB

- For unstable injuries of the ankle where a circumferential POP is not advisable, a backslab with a u-slab can be used.
- Circumferential velband is applied to the lower leg and foot and a wetted backslab is applied (which covers the posterior surface of the leg).
- A u-slab is applied which runs from the medial aspect of the leg, under the foot and finishing on the lateral aspect of the leg. The u-slab should overlap with the backslab and helps to prevent sideways movement of the ankle
- The ankle is held in plantargrade (ie 90 degrees)

BACK-SLAB WITH U-SLAB

- http://the.emergencyphysio.com/Files/Videos/Casting/bkuslab.mp4

ABOVE KNEE POP

- For tibial shaft or distal femoral fractures, an above knee pop may be used
- These splints should commences at the buttock crease and finish at the MTP joints as per the below knee backslab / casts.
- The knee should be immobilised in 30 degrees of flexion
- These should only be performed by experienced clinicians as these injuries have a higher risk of compartment syndrome

PLASTER SAW

- The plaster saw uses an oscillating blade to cut through plaster
- As the blade oscillates, friction is developed and if the blade is held in place for more than a few seconds, heat develops. If you haven't cut through the plaster after a second, bring the saw back up and rest for a second or so before continuing. Alternatively "score" the splint along the entire length that you wish to cut and then return to the start and repeat until you are through.
- The technique for using the plaster saw is a down/up motion (rather than with an angle grinder or regular saw where you cut through first and then continue across) with a slight twist of the wrists

PLASTER SAW

- http://the.emergencyphysio.com/Files/Videos/Casting/plastersaw.mp4

REMOVING A POP

- Cut through both sides of the splint
- Pry the plaster apart using the prying tool
- Cut through the padding on at least one side and you should be able to remove the POP

SPLITTING A POP

- If there are symptoms of neurovascular compromise which are not relieved by immediate elevation, the POP needs to be split (this would be done by the treating clinician, in consultation with senior medical staff as the initial injury might be unstable and it is important to investigate this prior to any action)

- Cut through the POP on both sides and pry the plaster apart using the prying tool

- Cut through the padding on BOTH sides and lightly bandage the POP back together.

SLINGS

BROAD ARM SLING

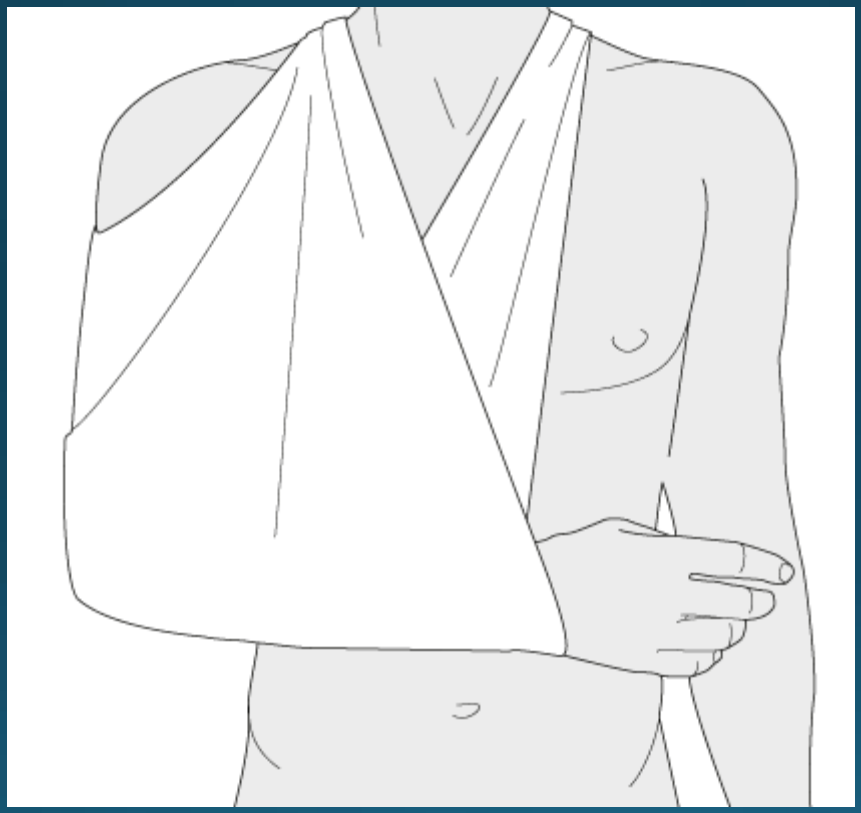

COLLAR AND CUFF

ELEVATION SLING

Patellofemoral Dislocation

- Easy when obviously still out
- May be underdiagnosed when not actually visualised though

https://www.youtube.com/watch?v=_RQURPifOnE

- Suspect when
  - Description of something going out and coming back in (by itself, low threshold)
  - Positive apprehension test
  - Tender around patella
  - Usually get a haemarthrosis – so swelling++
- Always
  - Make sure that can SLR
  - Ensure that doesn't have any other injury

Patellofemoral Dislocation

- Injured structures
  - Medial structures
    - Medial retinaculum
    - Medial patellofemoral ligament
  - Osteochondral
    - Damage to articular surface
    - Osteochondral fracture (patella / femur)
    - Avulsion # (medial patella)

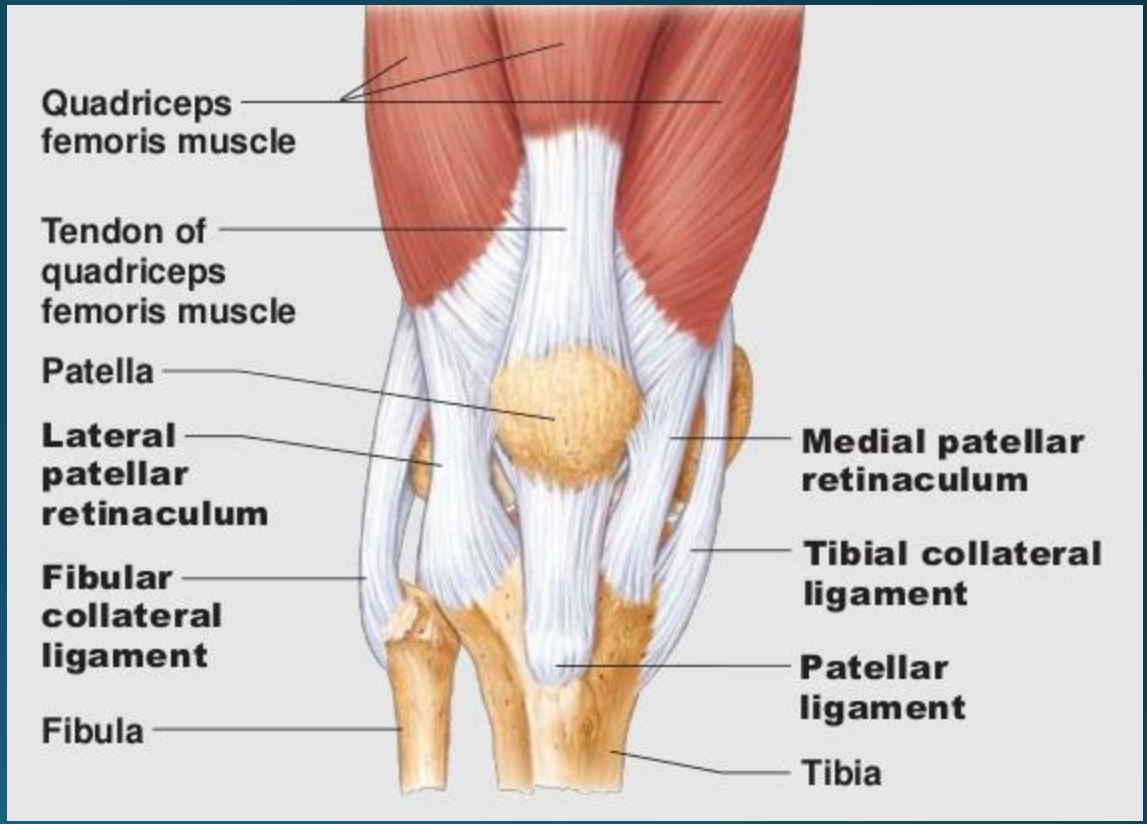

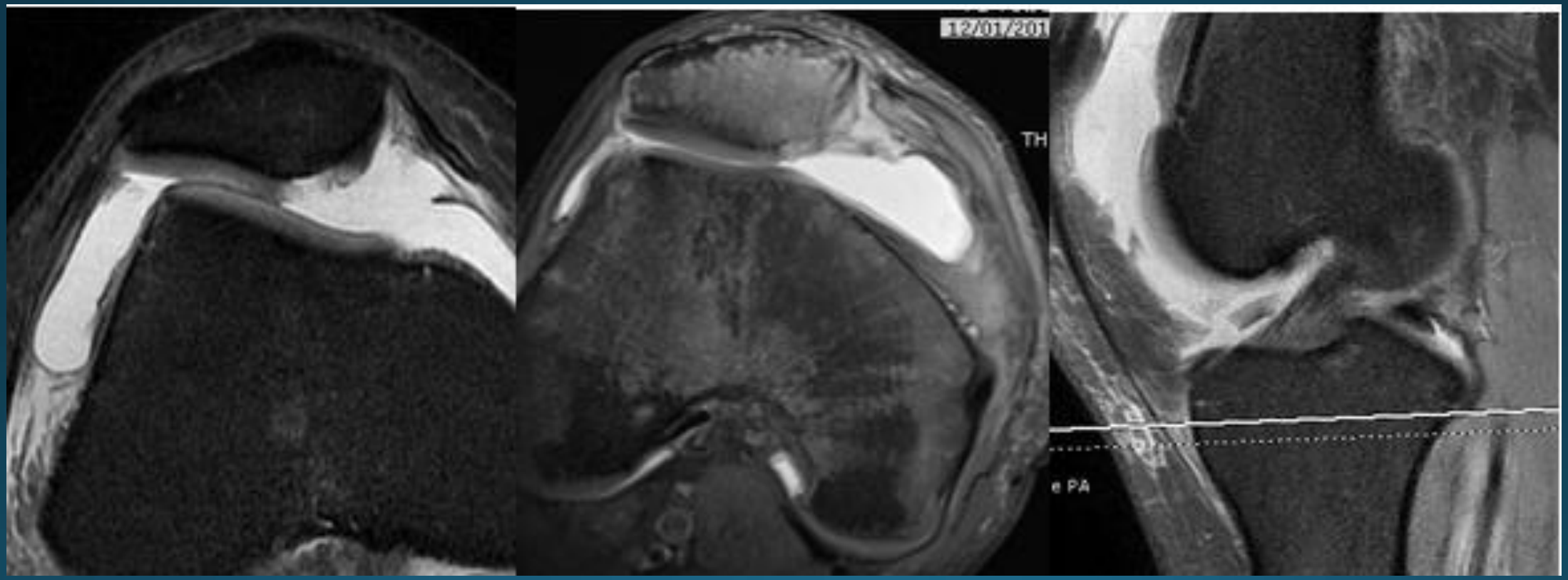
12/01/201
TH
e PA

Patellofemoral Dysfunction

- Contributing factors
  - Shallow trochlear groove
  - Lower limb biomechanics
    - Glutes, quads weakness
    - Hamstring, calf tightness

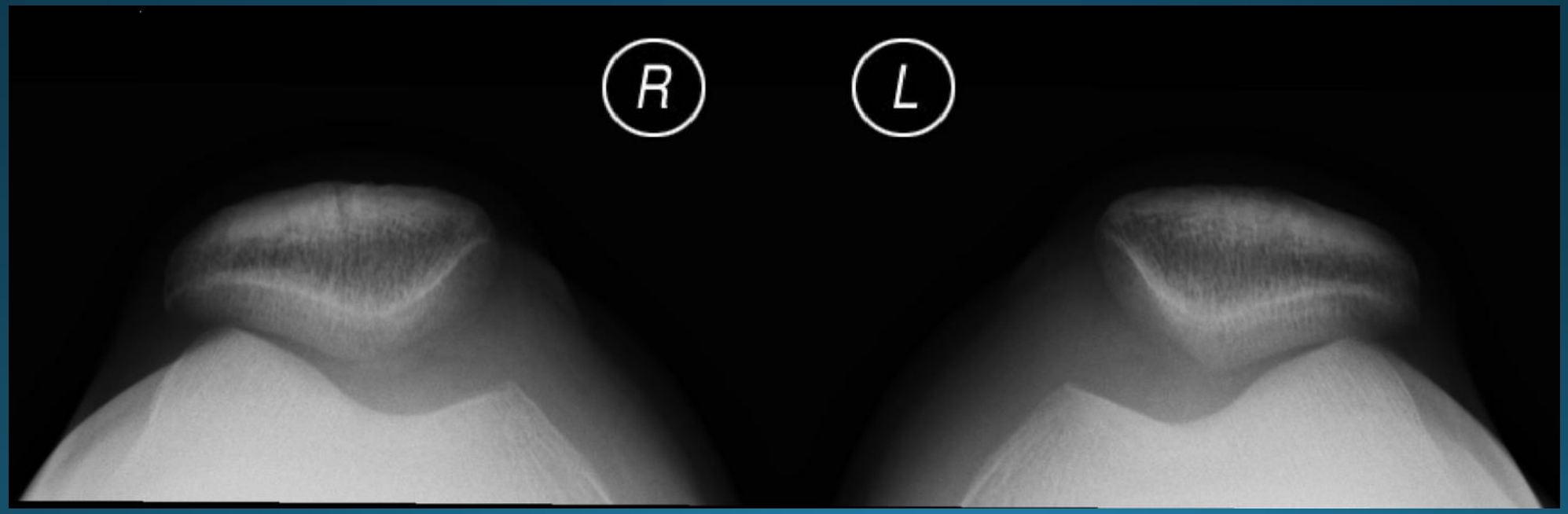

Patellofemoral dislocation

- Management
  - ZKS for 2-3/52 to allow damage structures to tighten / heal (until apprehension –ve)
  - WBAT
  - Physiotherapy for strengthening, rehabilitation
  - No sport for at least 6/52
  - 3 strikes and you're out – consider surgical options for repeat dislocations
    - Surgery not hugely successful and can be quite drastic compared to say ACL rupture as there are multiple contributing factors:
      - Tibial tubercle realignment
      - MPFL augmentation
      - Medial retinacular repair
      - Lateral release

Patellofemoral Dysfunction

- Contributing factors

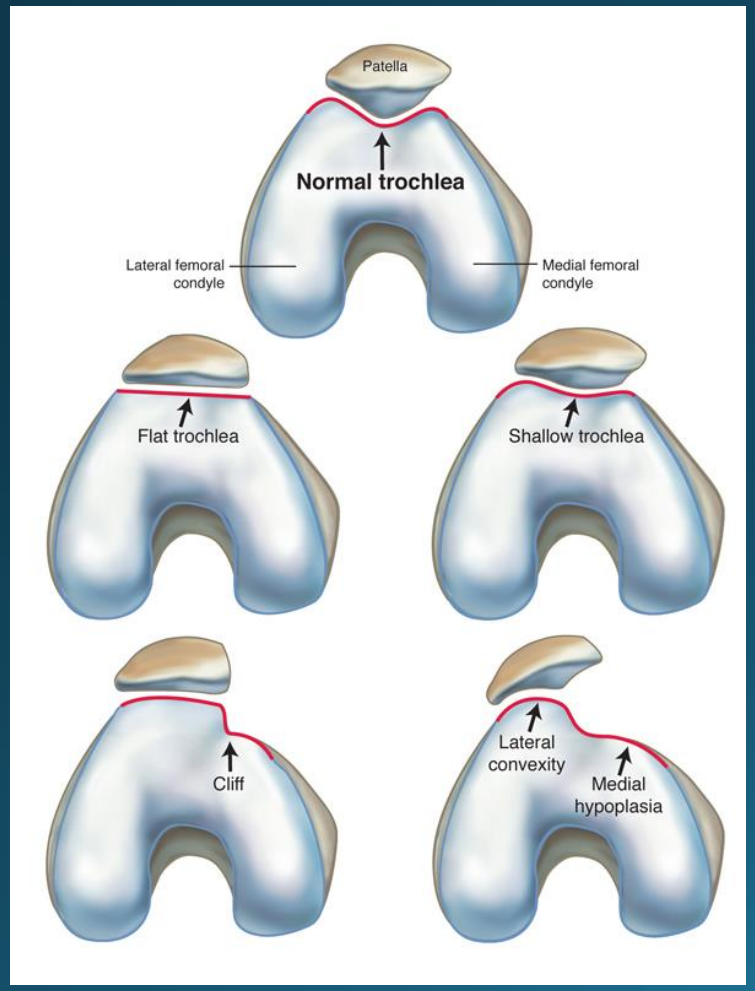

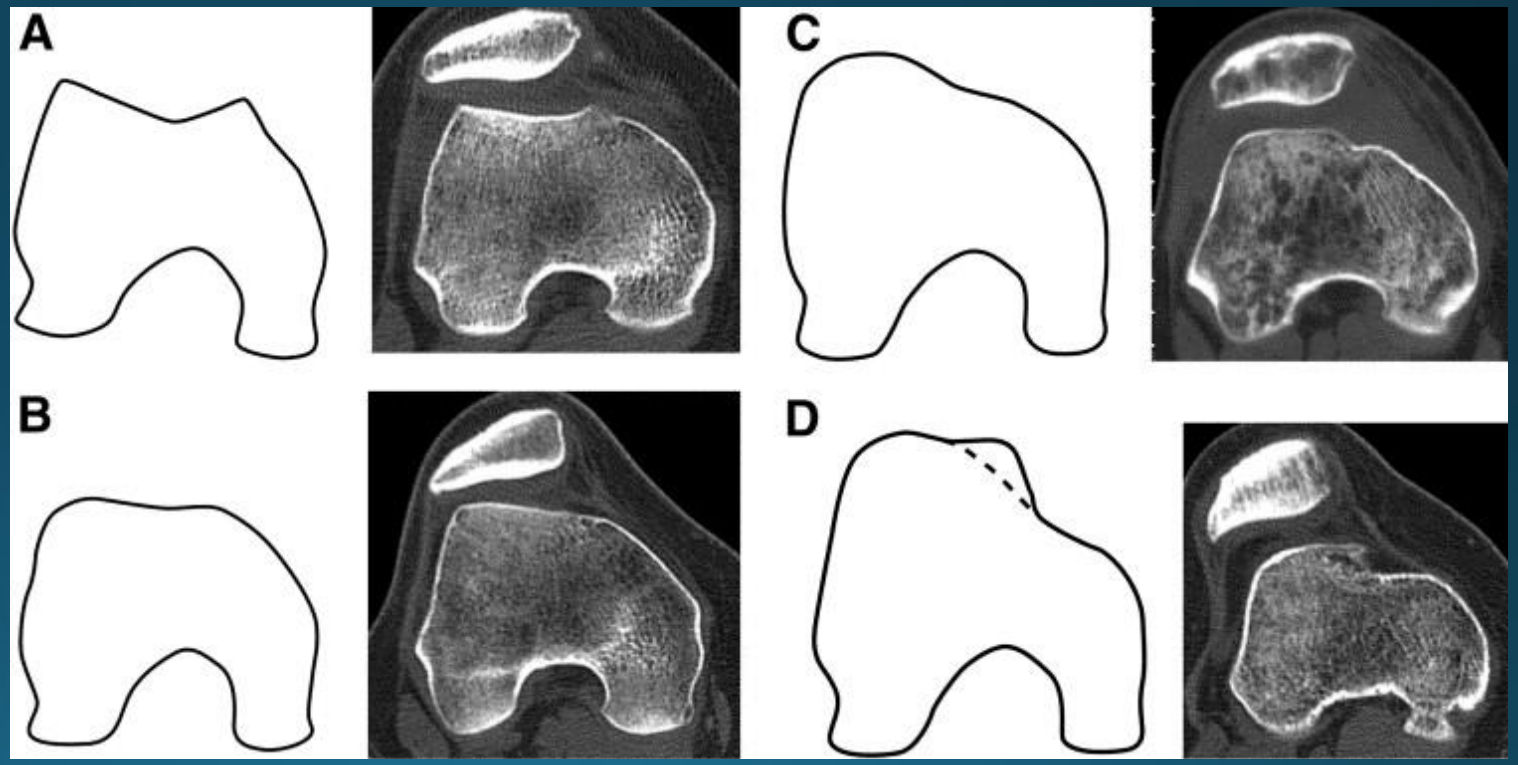

Pulled Elbow

- https://www.rch.org.au/clinicalguide/guideline_index/Pulled_elbow/

References

- The.emergencyphysio.com

- **Thermal Injury with Contemporary Cast-Application Techniques and Methods to Circumvent Morbidity.** Matthew A. Halanski, Amy D. Halanski, Ashish Oza, Ray Vanderby, Alejandro Munoz and Kenneth J. Noonan. *J Bone Joint Surg Am.* 2007;89:2369-2377. doi:10.2106/JBJS.F.01208