Wrist Injuries

Matt Woronczak

Advanced Musculoskeletal Physiotherapist – Emergency Department

Dandenong Hospital

www.nothinbutapeanut.com

The.emergencyphysio.com

Role of the Emergency Department

- Need to be mindful of WHAT IS IMPORTANT TODAY and hence what needs to be done right now:
  - Rule OUT significant pathology which might require immediate or prompt attention
    - Know your population, including what injuries are likely and which significant injuries need to be ruled out
  - Appropriately manage identified pathology and refer on to most appropriate service

Role of Imaging

- X-rays and other diagnostic imaging modalities may form a PART of the assessment of a limb injury, but they are not the FULL assessment

- The patient should be examined as thoroughly as possible and a decision made as to whether imaging might be indicated and what the most appropriate modality might be

- It is not always possible to perform a complete examination using all available tests on someone with an acute injury, due to pain / swelling. It is therefore important to realise the tests which are going to help rule out the most significant pathology

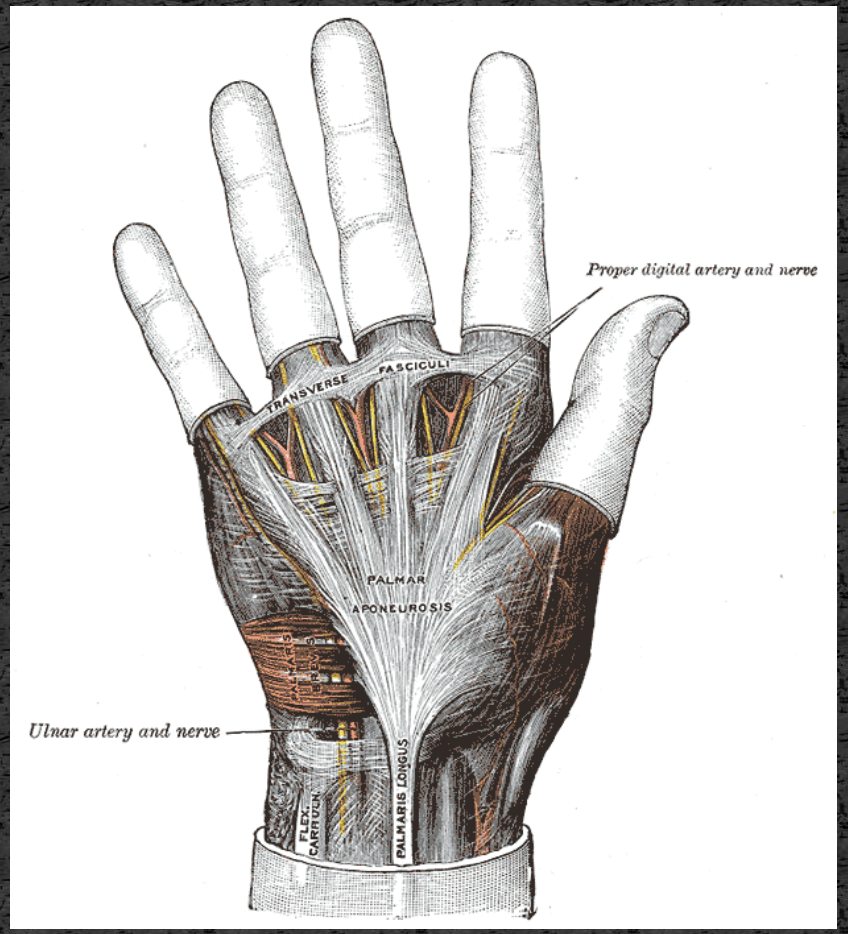
Proper digital artery and nerve
TRANSVERSE
FASCICULI
PALMAR
APONEUROSIS
Ulnar artery and nerve
FLEX. CARPI UN.
PALMARIS LONGUS

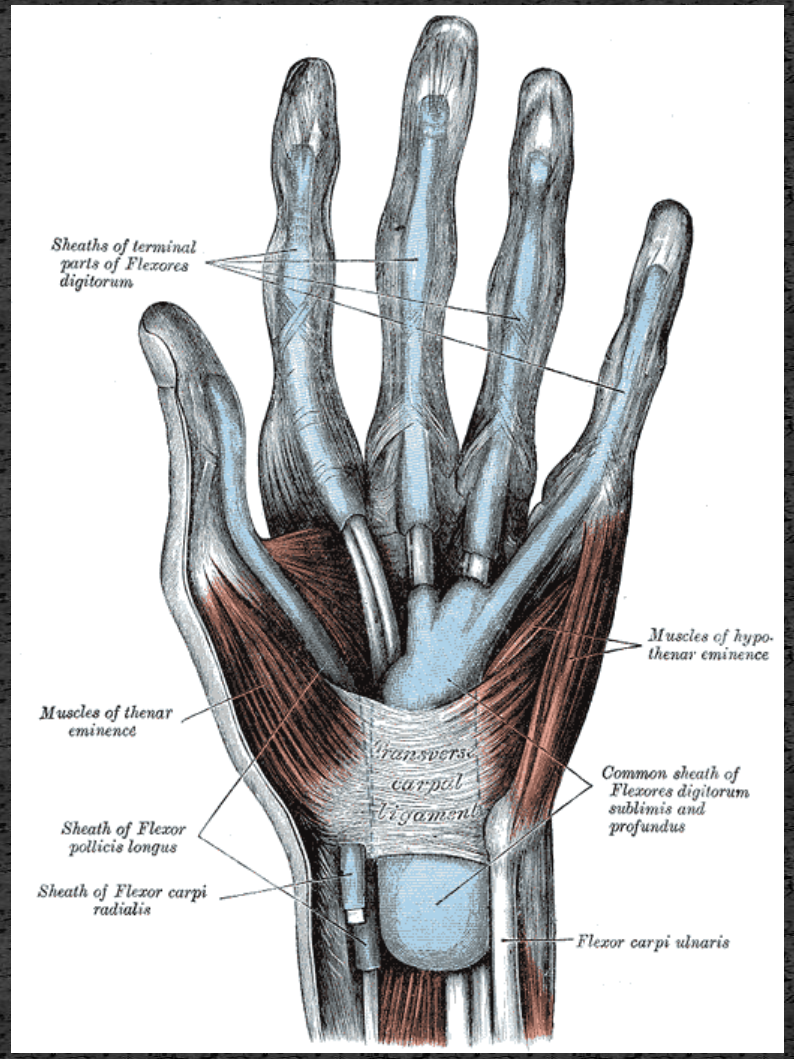
Sheaths of terminal parts of Flexores digitorum
Muscles of hypothenar eminence
Muscles of thenar eminence
Transverse carpal ligament
Common sheath of Flexores digitorum sublimis and profundus
Sheath of Flexor pollicis longus
Sheath of Flexor carpi radialis
Flexor carpi ulnaris

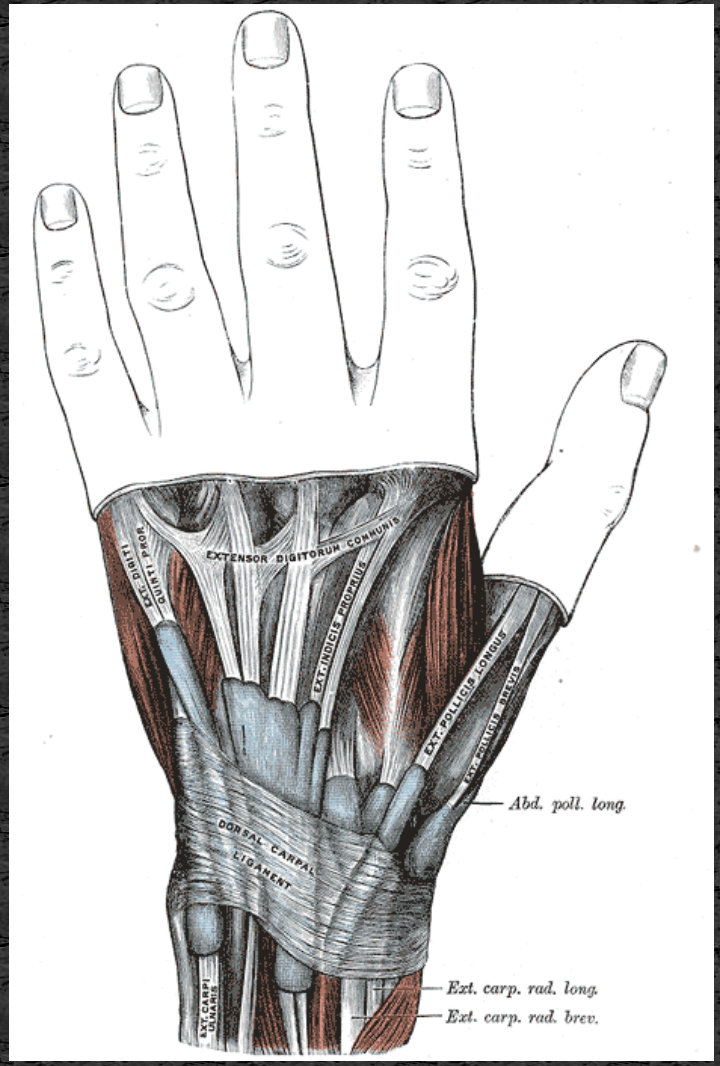
EXTENSOR DIGITORUM COMMUNIS
EXT. DIGIT. QUINTI PROPR.
EXT. INDICIS PROPRIUS
EXT. POLLICIS LONGUS
EXT. POLLICIS BREVIS
Abd. poll. long.
DORSAL CARPAL LIGAMENT
EXT. CARPI ULNARIS
Ext. carp. rad. long.
Ext. carp. rad. brev.

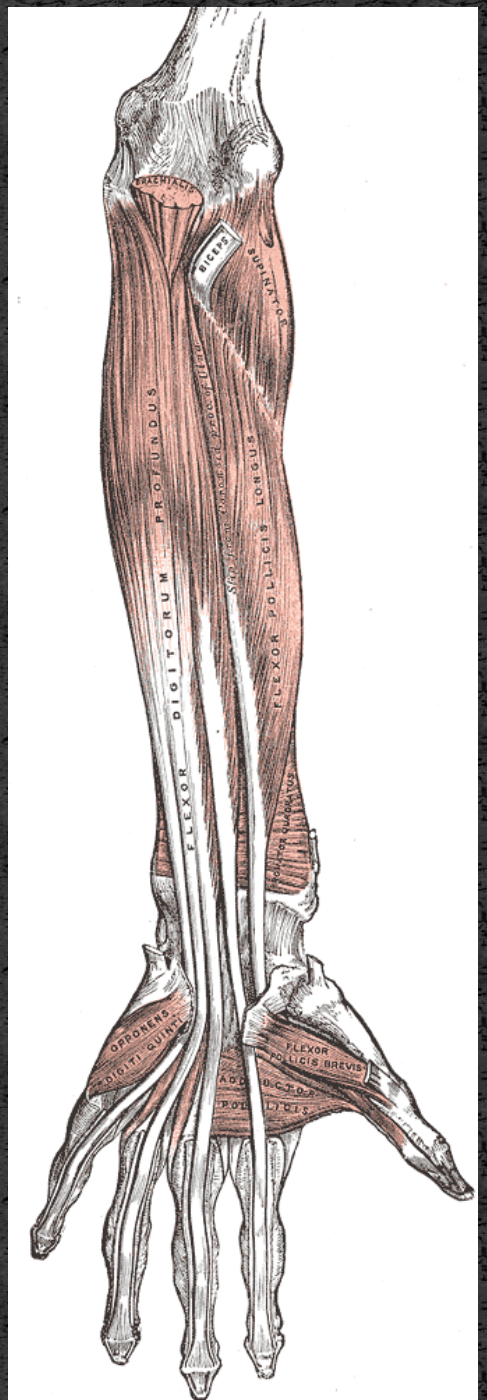
BRACHIALIS
BICEPS
SUPINATOR
FLEXOR DIGITORUM PROFUNDUS
FLEXOR POLLICIS LONGUS
OPPONENS DIGITI QUINTI
FLEXOR POLLICIS BREVIS

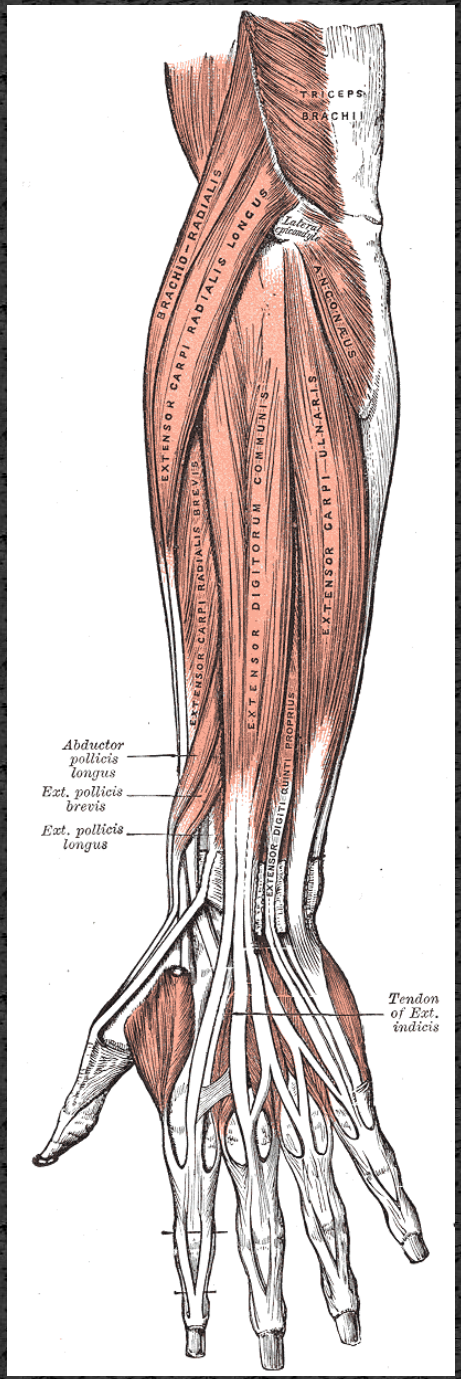
TRICEPS BRACHII
BRACHIO-RADIALIS
EXTENSOR CARPI RADIALIS LONGUS
Lateral epicondyle
ANCONAEUS
EXTENSOR CARPI RADIALIS BREVIS
EXTENSOR DIGITORUM COMMUNIS
EXTENSOR CARPI ULNARIS
EXTENSOR DIGITI QUINTI PROPRIUS
Abductor pollicis longus
Ext. pollicis brevis
Ext. pollicis longus
Tendon of Ext. indicis

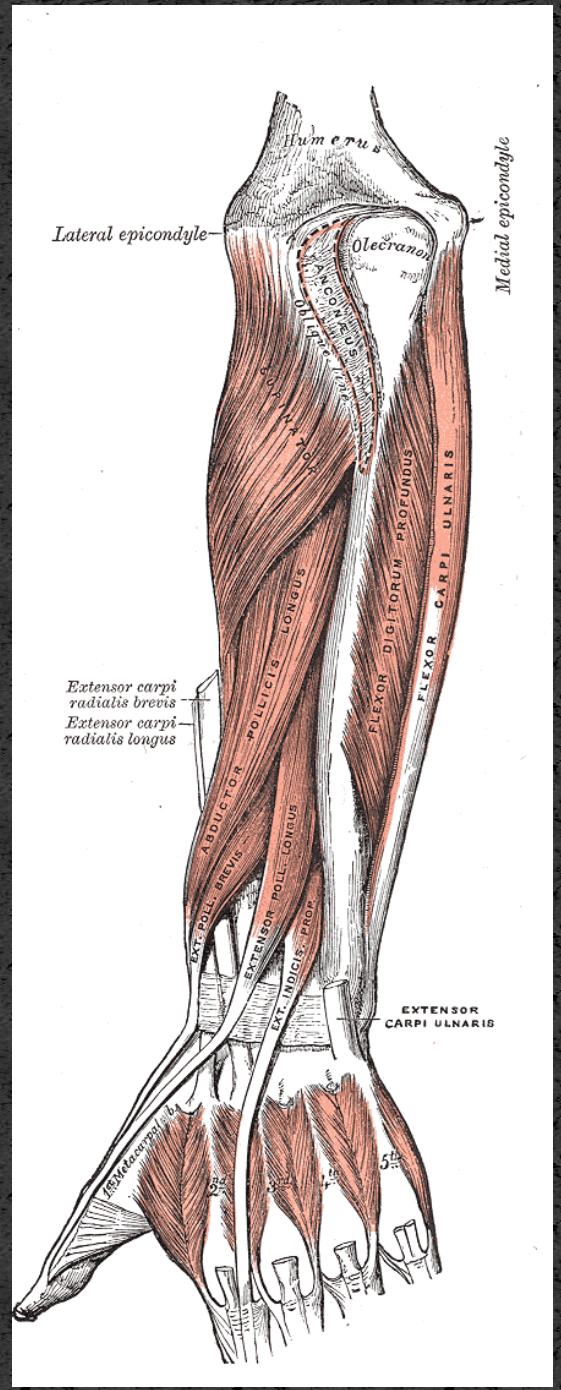
Humerus
Lateral epicondyle
Olecranon
Medial epicondyle
ANCONAEUS
OBLIQUE LINE
FLEXOR DIGITORUM PROFUNDUS
FLEXOR CARPI ULNARIS
Extensor carpi radialis brevis
Extensor carpi radialis longus
ABDUCTOR POLLICIS LONGUS
EXT. POLL. BREVIS
EXTENSOR POLL. LONGUS
EXT. INDICIS PROP.
EXTENSOR CARPI ULNARIS
1st Metacarpal b.
2d
3d
4th
5th

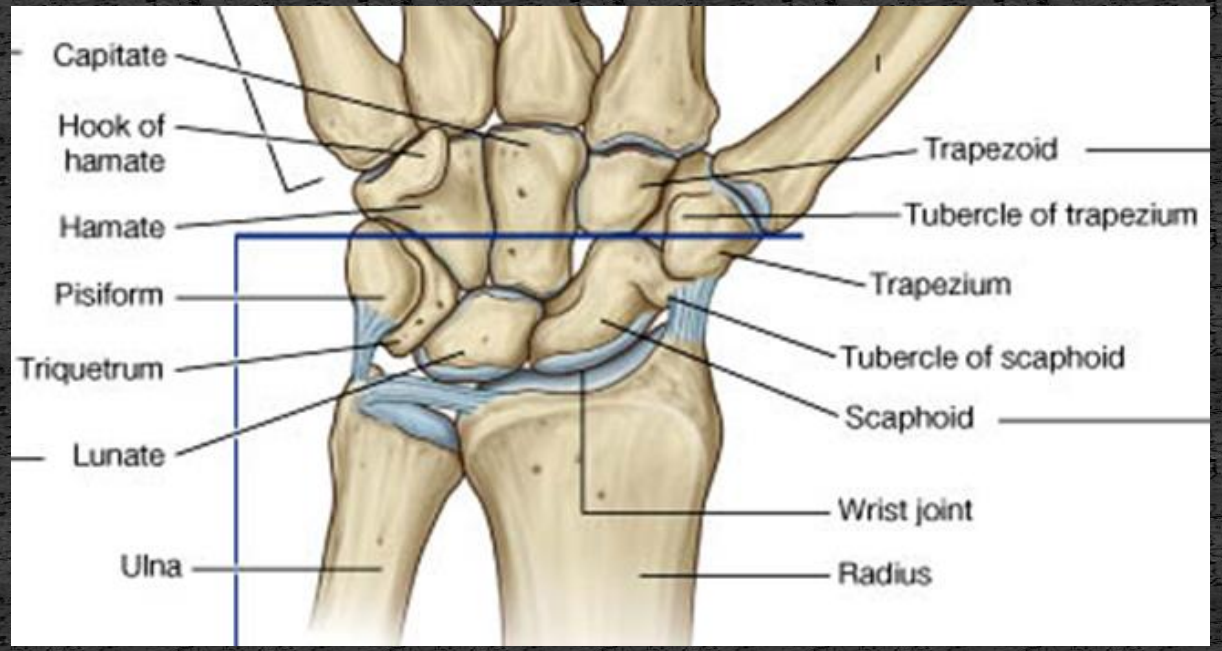
Capitate
Hook of hamate
Hamate
Pisiform
Triquetrum
Lunate
Ulna
Trapezoid
Tubercle of trapezium
Trapezium
Tubercle of scaphoid
Scaphoid
Wrist joint
Radius

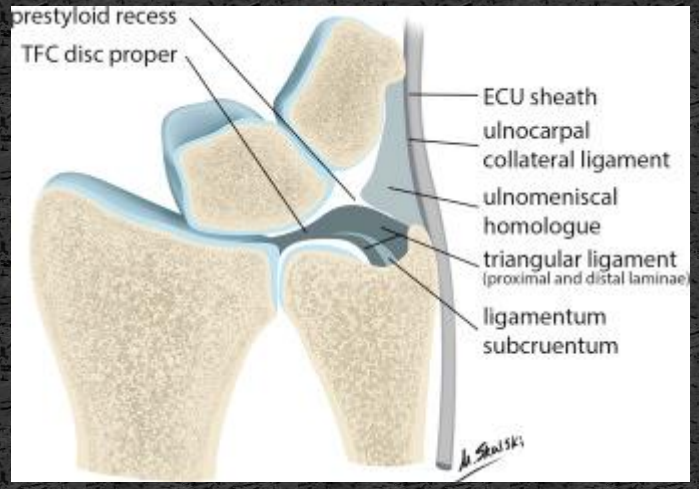
prestyloid recess
TFC disc proper
ECU sheath
ulnocarpal collateral ligament
ulnomeniscal homologue
triangular ligament
(proximal and distal laminae)
ligamentum subcruentum

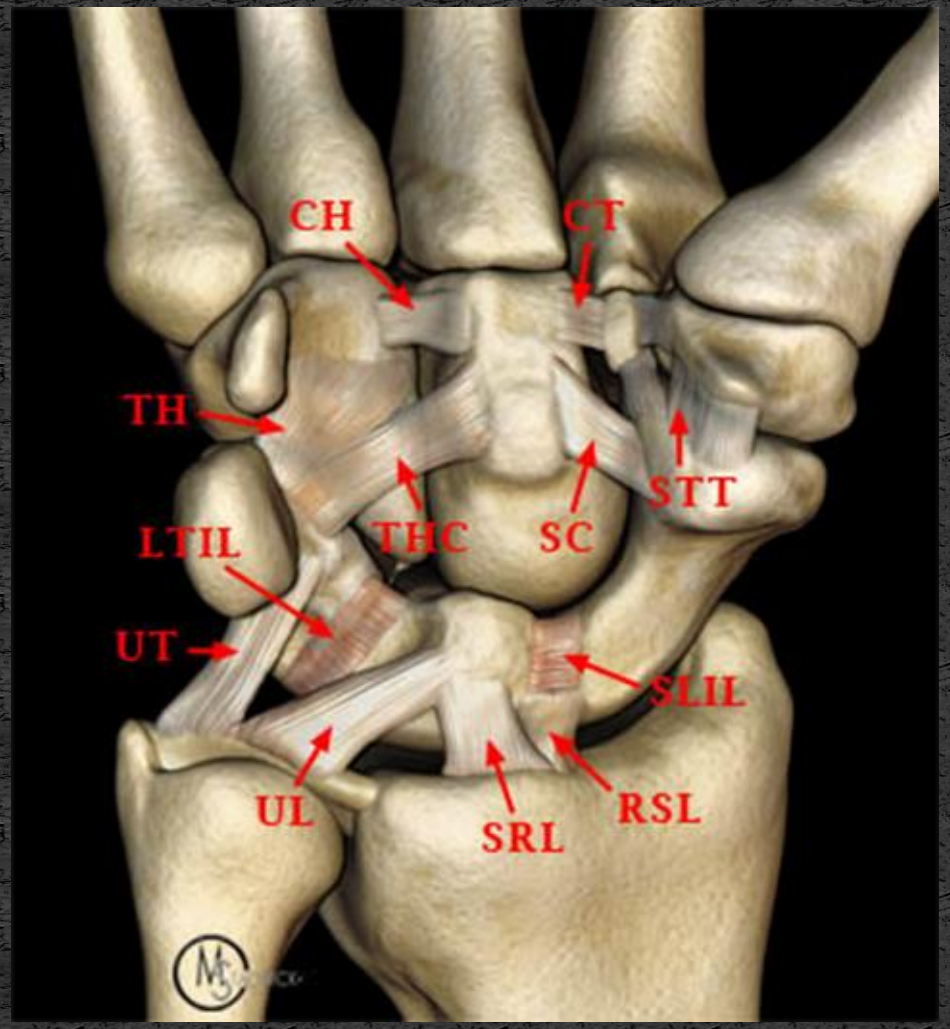
CH
CT
TH
STT
THC
SC
LTIL
UT
SLIL
UL
SRL
RSL

WRIST ASSESSMENT

Wrist

- What do we want to rule out?
  - Neurovascular compromise
  - Fracture
  - Dislocation
  - Significant soft tissue injury
    - Tendon injury
  - Infection
  - Foreign bodies
  - Weird bony problems
    - Cysts
    - Tumours
    - Pagets, etc

Wrist Assessment

- Subjective
  - If acute injury, get an idea:
    - Mechanism (understand the forces involved)
      - Longitudinal force
      - Hyperextension , Hyperflexion, etc
      - Cracks / Pops
    - Ability to continue
    - Management so far

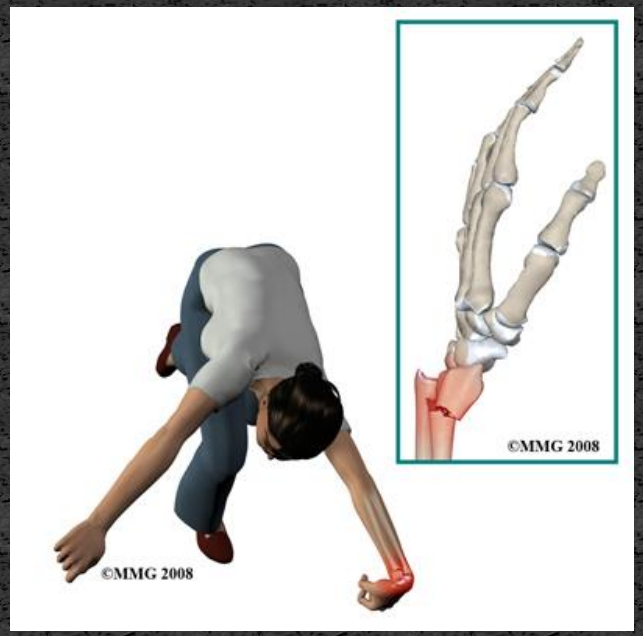

Wrist and Hand Assessment

- Subjective
  - Ask if any problems in that area before
    - How long has it been there?
    - What tends to stir it up?
    - What helps?
    - How long does it take to settle after activity?
    - How is it the next day? (especially in the morning)
    - Investigations / management
  - Handedness
  - Enquire about activity level (including occupation, sports)
    - Type
    - Duration
    - Frequency

Wrist Assessment

- Observation
  - Remove all rings / jewellery

Wrist Assessment

- Observation
  - Deformity, Swelling
  - Redness, heat

Wrist Assessment

- Observation
  - Expose the part up to the next joint that is not affected

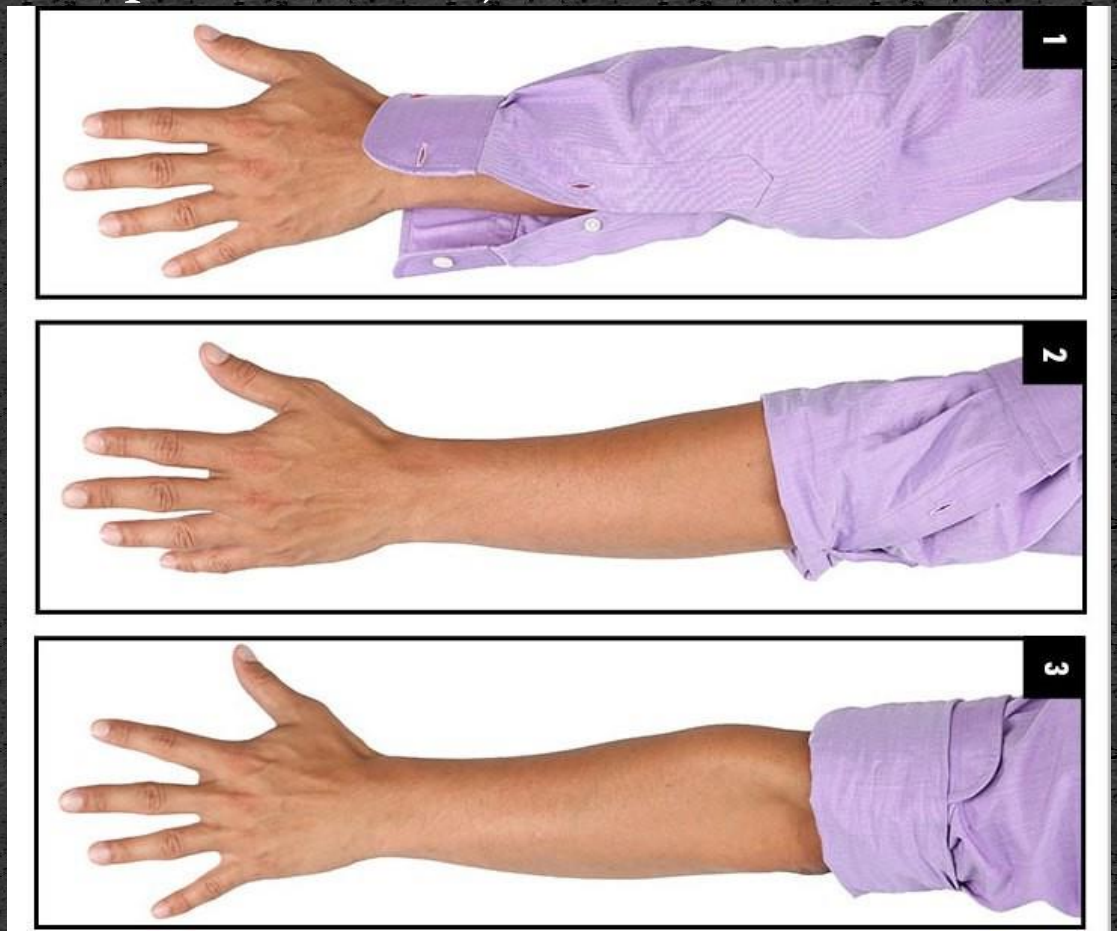

Wrist Assessment

- Observation
  - Distal neurovascular function
    - Colour, Movement, Warmth, Sensation
    - Capillary Return
    - Peripheral Pulses
    - Nerve function
      - Radial
      - Median
        - Anterior Interosseus Nerve
      - Ulnar

  - 8% of children with upper limb fractures have a nerve injury*

ROCK, PAPER, SCISSORS, OK': INTRODUCTION OF A SIMPLE GUIDELINE TO IMPROVE NEUROLOGICAL ASSESSMENT IN PAEDIATRIC PATIENTS PRESENTING WITH UPPER LIMB FRACTURES
A.G. Marsh, J. Robertson, A. Godman, J. Boyle, J. Huntley

Wrist Assessment

- AROM / PROM of wrist
  - Flexion / Extension
  - Radial Deviation / Ulnar Deviation
- Also need to consider joints above and below
  - Elbow – flexion / extension / supination / pronation
  - Fingers – flex / ext (long finger flexor/ extensors)
- Power
  - Grip (maybe)

Wrist Assessment

- Palpation
  - From elbow down to finger tips
  - Bony tenderness, in particular:
    - Scaphoid Tubercle
    - Snuff Box

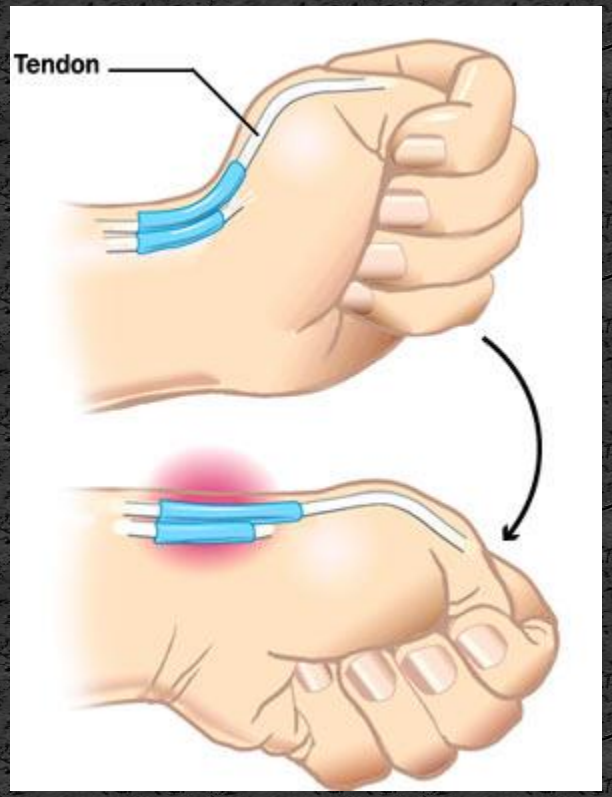

- Special Tests
  - Longitudinal Compression through the thumb
  - Finklestein's Test
  - Tinel's Sign
  - Phalen's Sign

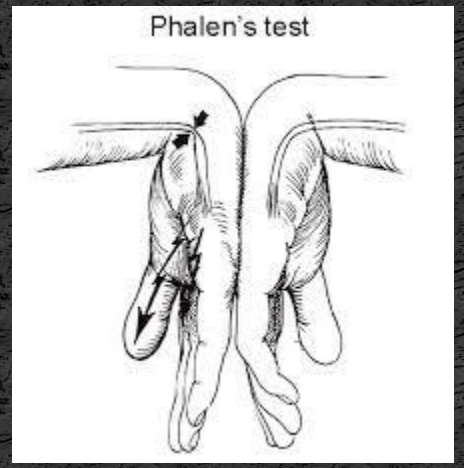

Deciding to Image

- X-rays expose the patient to radiation, so we want to minimise the risk
  - Does it need to be done at all?
    - No commonly used decision making tools for general wrist imaging
    - Given importance of hand (and hence wrist) function, generally have a low threshold for imaging
      - Deformity
      - Swelling
      - Reduced ROM
      - Bony tenderness
  - Have they had images taken prior to coming here that they do not have with them?
    - Can we view them online?
    - Can we get them transferred across from another site
  - Are they (or could they be) pregnant? (on Symphony asks from 12-60)
    - If could be – urine pregnancy test

Imaging Modalities

Modality	Use	Radiation Dose (mSv)	Equivalent Normal Background Radiation	Increased risk of Ca from Ix
X-ray	Bony pathology, foreign bodies	0.005	< 1 day	1 in 11,000,000
CT	Clarification and classification of fracture	0.15	1 month	1 in 76,000
Bone Scan	Suspicion of malignancy; was previously used for potential stress injury but out of favour now with MRI	6.3	1.8 years	1 in 1,800
Ultrasound	Identification of soft tissue problems (ambiguous tendon pathology, ? UCL rupture) or foreign bodies not visible on x-ray	Nil	N/A	N/A
MRI	Soft tissue injuries where diagnosis is unclear; can show bone marrow oedema / fractures as well (although CT better for just bone)	Nil	N/A	N/A

Deciding to Image

- Remove clothing where possible
  - Creates a shadow

Principles of X-rays

- X-rays are a 2-dimensional representation of a 3-dimensional structure

- As such, we ALWAYS need AT LEAST 2 orthogonal views (ie at 90 degrees to each other – usually at least an AP or PA and a lateral)
  - There are also special views for particular areas or when looking for particular pathologies

- Each of the views are relative to the part requested
  - For the wrist, the images are AP and lateral to the WRIST
  - For the forearm views, although the wrist is included, the images are AP and lateral to the RADIUS and ULNA.

Standard Wrist Views

Wrist - PA

Wrist – Oblique

Wrist – Lateral

Other Views

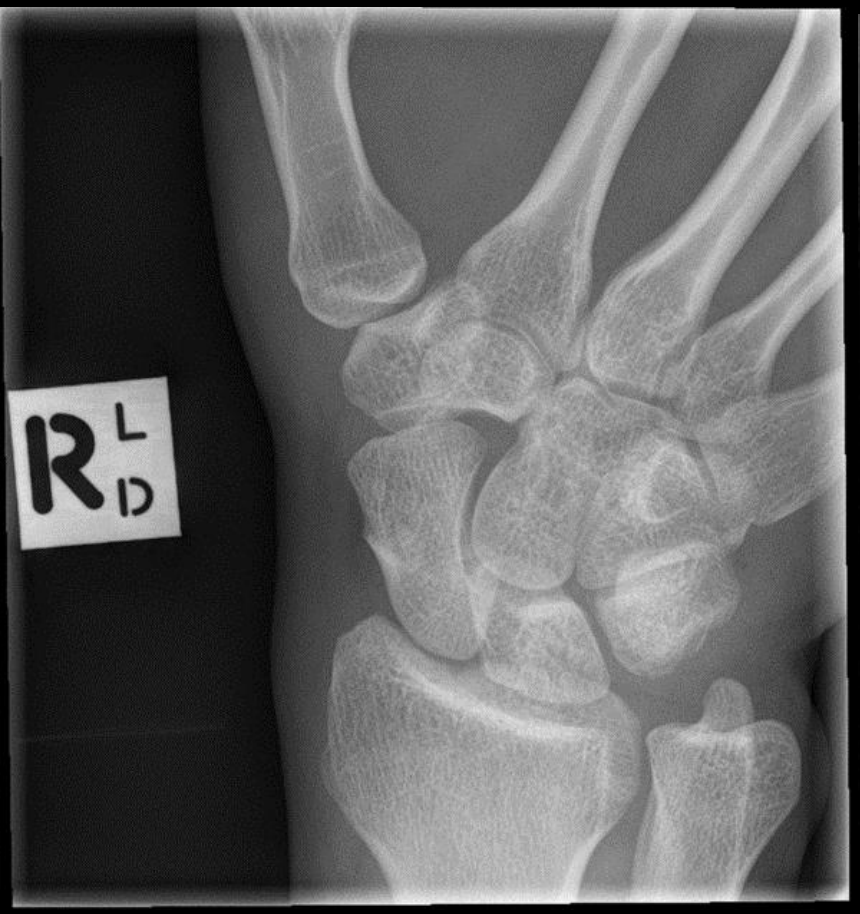

Scaphoid PA (Ulnar Deviation)

Clenched Fist Views


L


L

Principles of X-rays

- SYSTEMATIC APPROACH TO INTERPRETATION
  - First Impression
    - Anything obvious?
  - A
    - Adequacy
      - Neither under (too light) or over exposed (too dark)
      - Joints above and below the area of concern are visualised
    - Alignment
      - The type of x-ray views taken and the anatomical site visualised

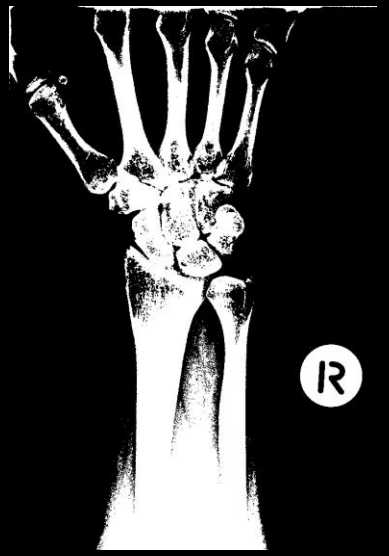

Principles of X-rays

- B
  - Bones
    - Outline
      - The contours of the bone should be followed and any abnormality commented on
    - Density
      - Look at each bone in sequence and comment on whether it is:
        - Radiolucent = thinner bone (eg osteopenic)
        - Radioopaque = thicker than surrounding bone (eg Paget's disease, chronic osteomyelitis, osteochondritis)
      - Check for trabecular interruption

Principles of X-rays

- C
  - Cartilage
    - Outline
    - Joint space
    - Loose bodies
- D
  - Don’t stop
    - Complete a full assessment of the entire image – don’t just stop when you find something!

Describing Findings

- Describe
  - Swelling
  - Foreign objects
  - Wounds
  - Fractures
  - Dislocations
  - Other bony findings eg ossicles

- Know your ANATOMY!

Describing Findings

- Location
  - Anatomical
    - Proximal / Distal
      - Long bones are divided into thirds - proximal, middle and distal

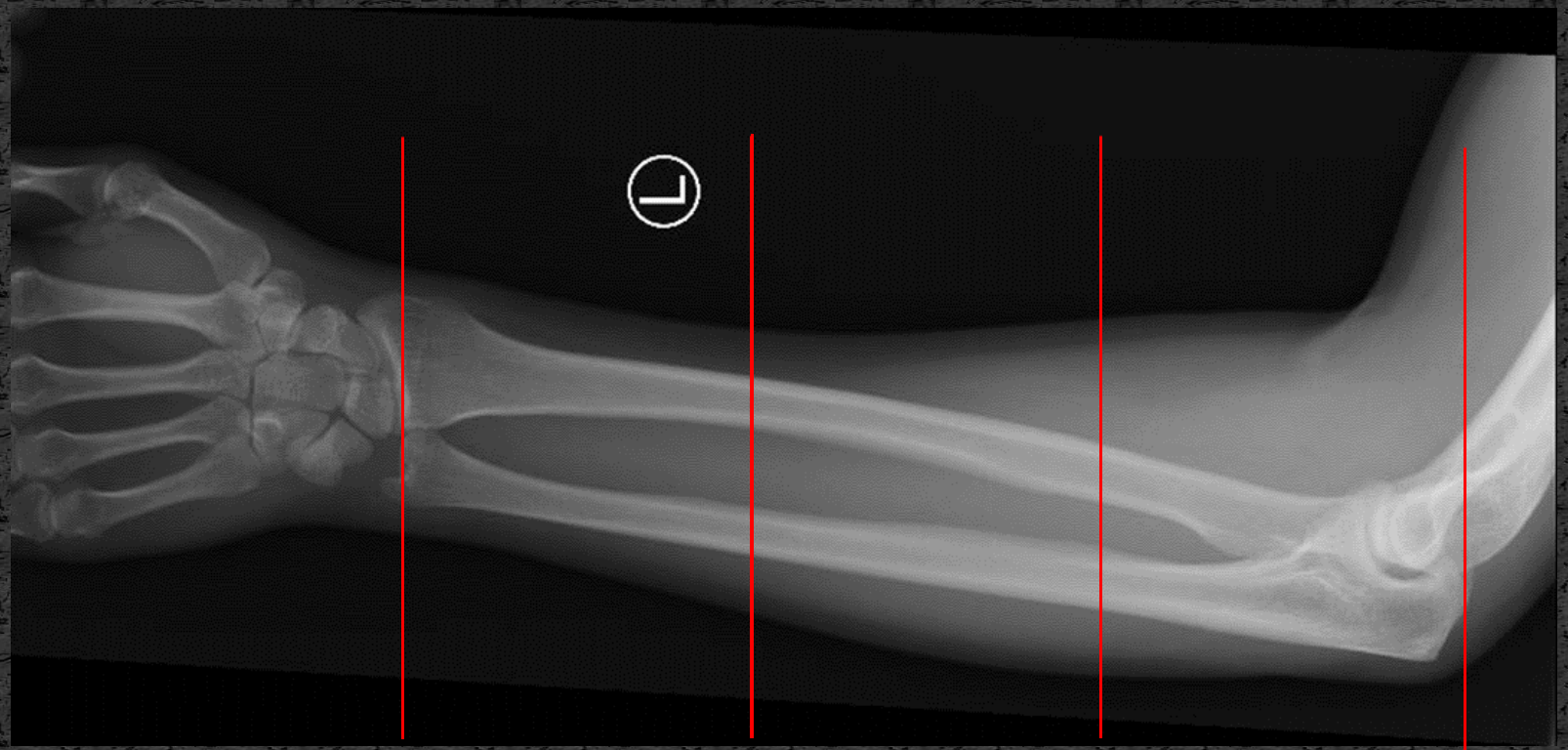

Epiphysis

Epiphyseal Plate

Metaphysis

Diaphysis (shaft)

Salter-Harris fracture types

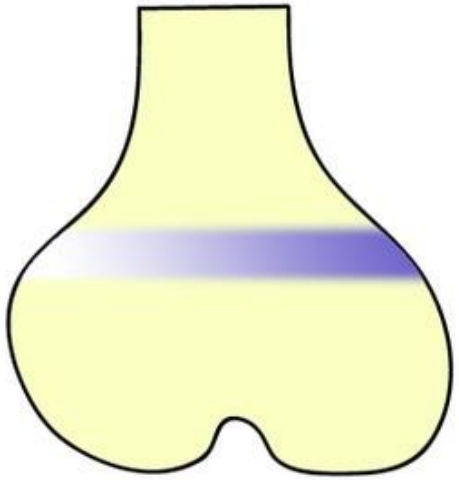

Normal

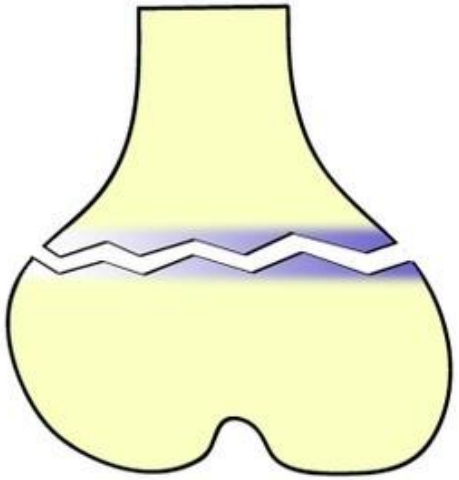

Type 1 - 5%

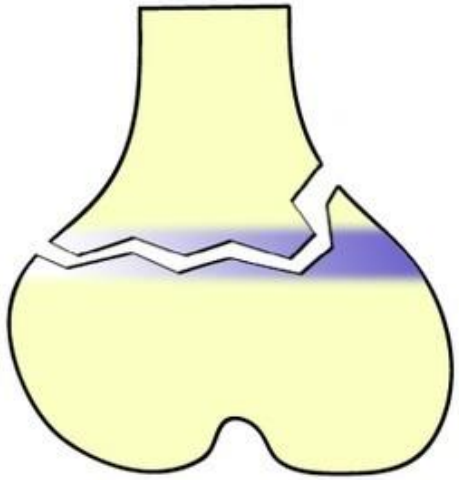

Type 2 - 75%

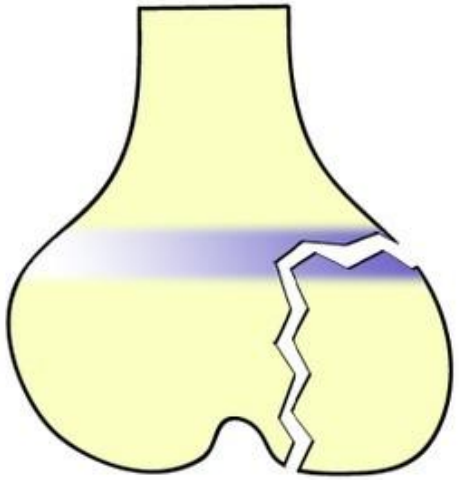

Type 3 - 10%

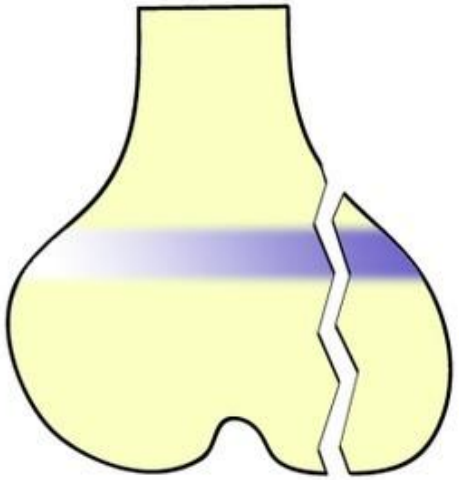

Type 4 - 10%

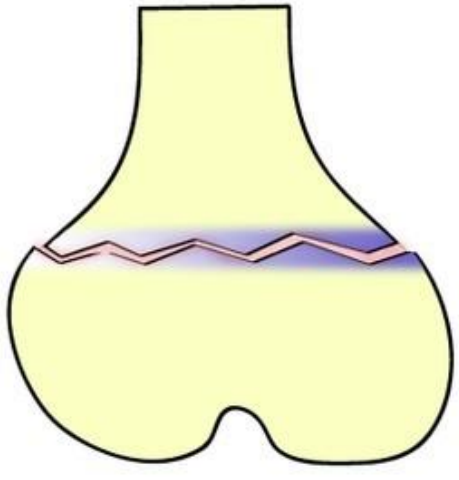

Type 5 - uncommon

Describing Findings

- Location
  - Anatomical

Ulnar side (not “medial”)

Radial side (not “lateral”)

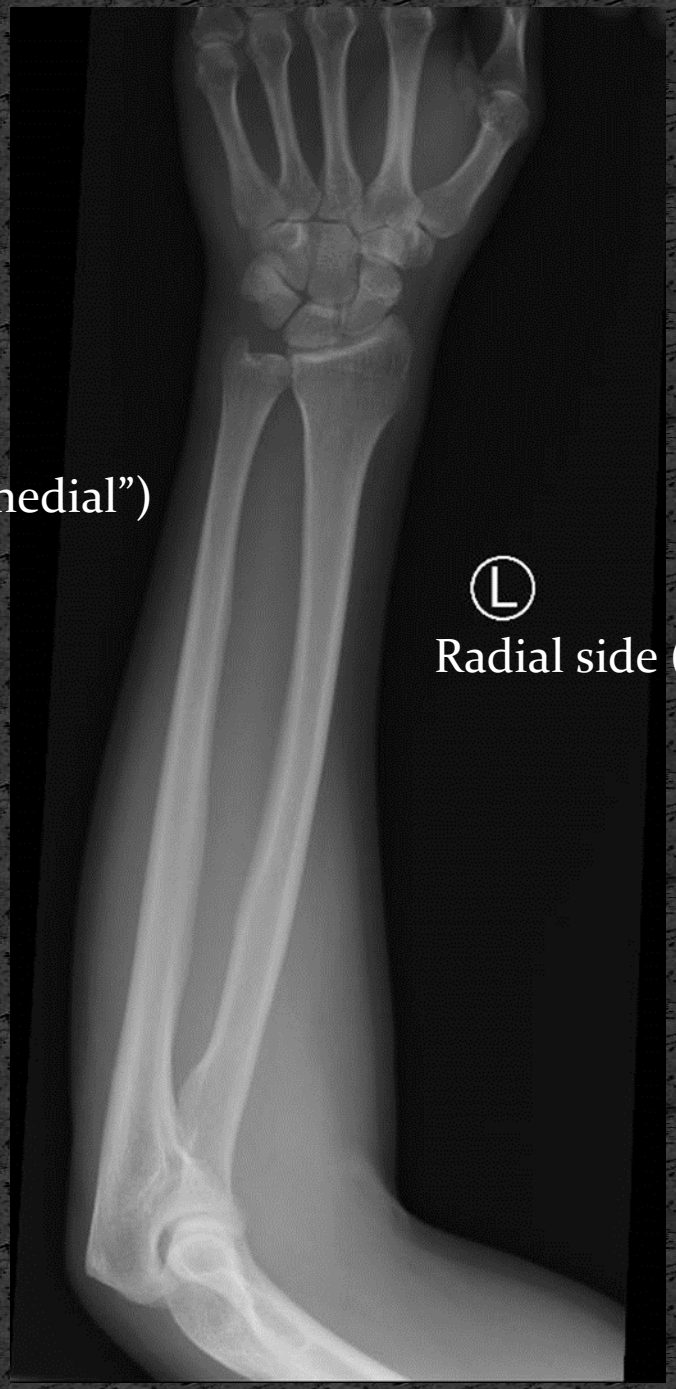

Dorsal (not “posterior”)

Volar (not “anterior”)

Palmar (not “anterior”)

Describing Findings

- Location
  - Bony landmarks
    - Radial styloid / ulnar styloid
    - Scaphoid waist / proximal pole / distal pole / tubercle

Describing Findings

- Sclerotic
  - Area of increased density
    - Osteoarthritis = subchondral sclerosis
    - Impacted fracture

- Lytic
  - Lysis – hole = less dense area (eg bony cyst)

Describing Findings

- Radiolucent / Radiodense
  - Allows radiation to pass freely = transparent (more dark)
  - Eg fracture line

- Radio-opaque
  - Obstructs passage of radiant energy (more white)
  - Eg metal

Describing Fractures

- Pattern
  - Transverse / Horizontal
  - Vertical / Longitudinal
  - Oblique
  - Spiral
  - Comminuted
  - Stellate
  - Depressed

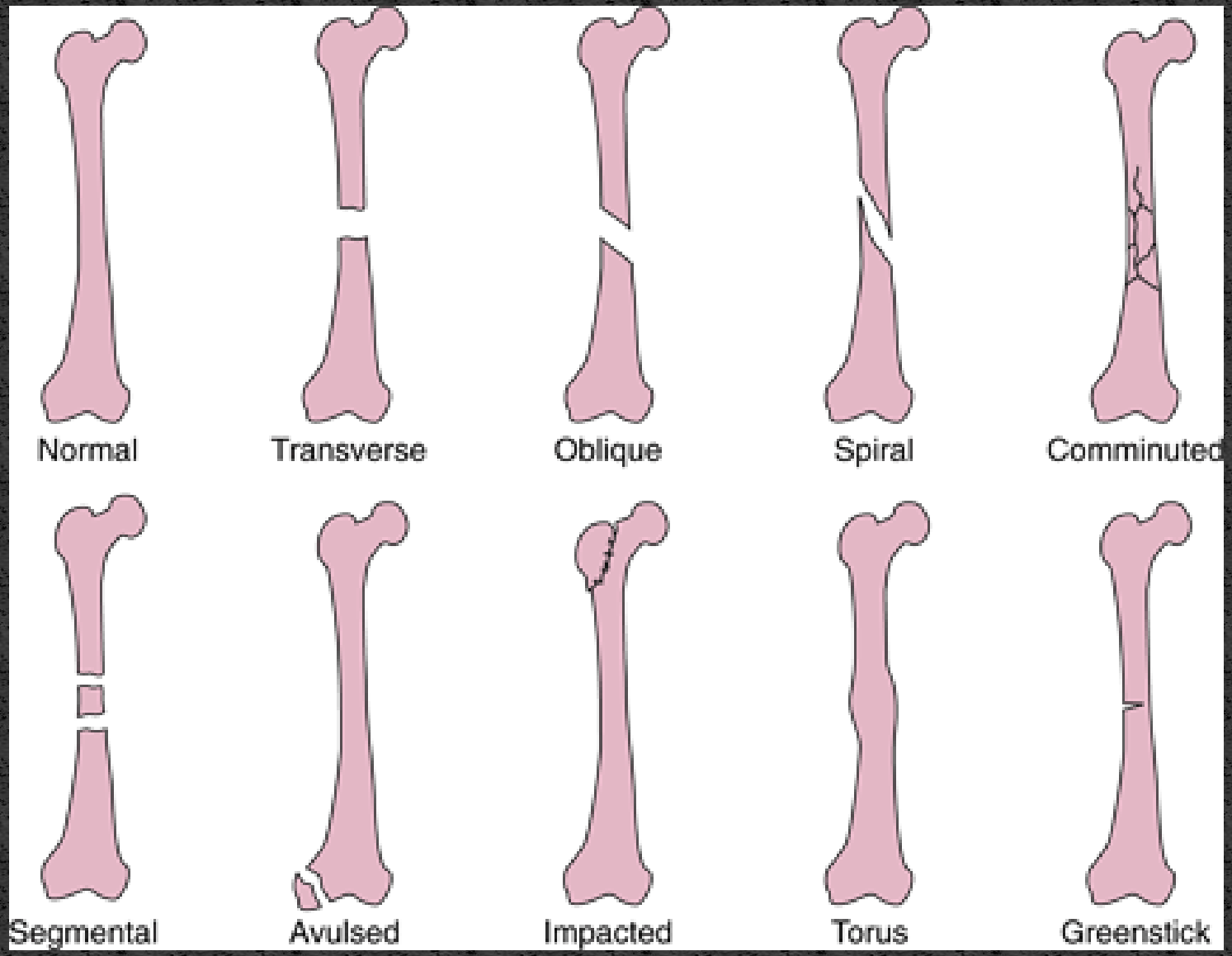

Describing Fractures

- Displacement
  - Undisplaced
  - Displaced
    - Describe the distal segment relative to the proximal segment, in the anatomical position

- Articular
  - Extra-articular
  - Intra-articular
    - Step / defect

- Angulation
  - Discuss in terms of the distal segment relative to the proximal segment in the anatomical position

Describing Subluxations and Dislocations

- Location
  - Which joint
    - Eg Distal radioulnar joint
    - Eg Radiocarpal joint

- Subluxation / Dislocation
  - Subluxation = Partial loss of joint congruency
  - Dislocation = Complete loss of joint congruency

- Pattern
  - Which direction (relative to the anatomical position)
    - Posterior / Anterior

- Other injury
  - Is there associated bony injury (see previous slide)

PA

Positioning and Alignment For Image

- Pt sitting on chair at edge of table
- Elbow bent to 90, pronation
- Volar forearm and palm flat on plate
- Fingers curled under to arch hand slightly

Checking the Orientation of the Film

- Equal concavity of each sides of the shafts of the proximal metacarpals
- Near equal distances between the proximal metacarpals (the bases overlap though)
- Separation of the distal radius and ulna is present, except for possible minimal superimposition of the distal radioulnar joint.

Checking the Exposure of the Film

- Trabecular markings of all bones should be visible and appear sharp.
- Soft tissue detail should be visible.

PA

PA

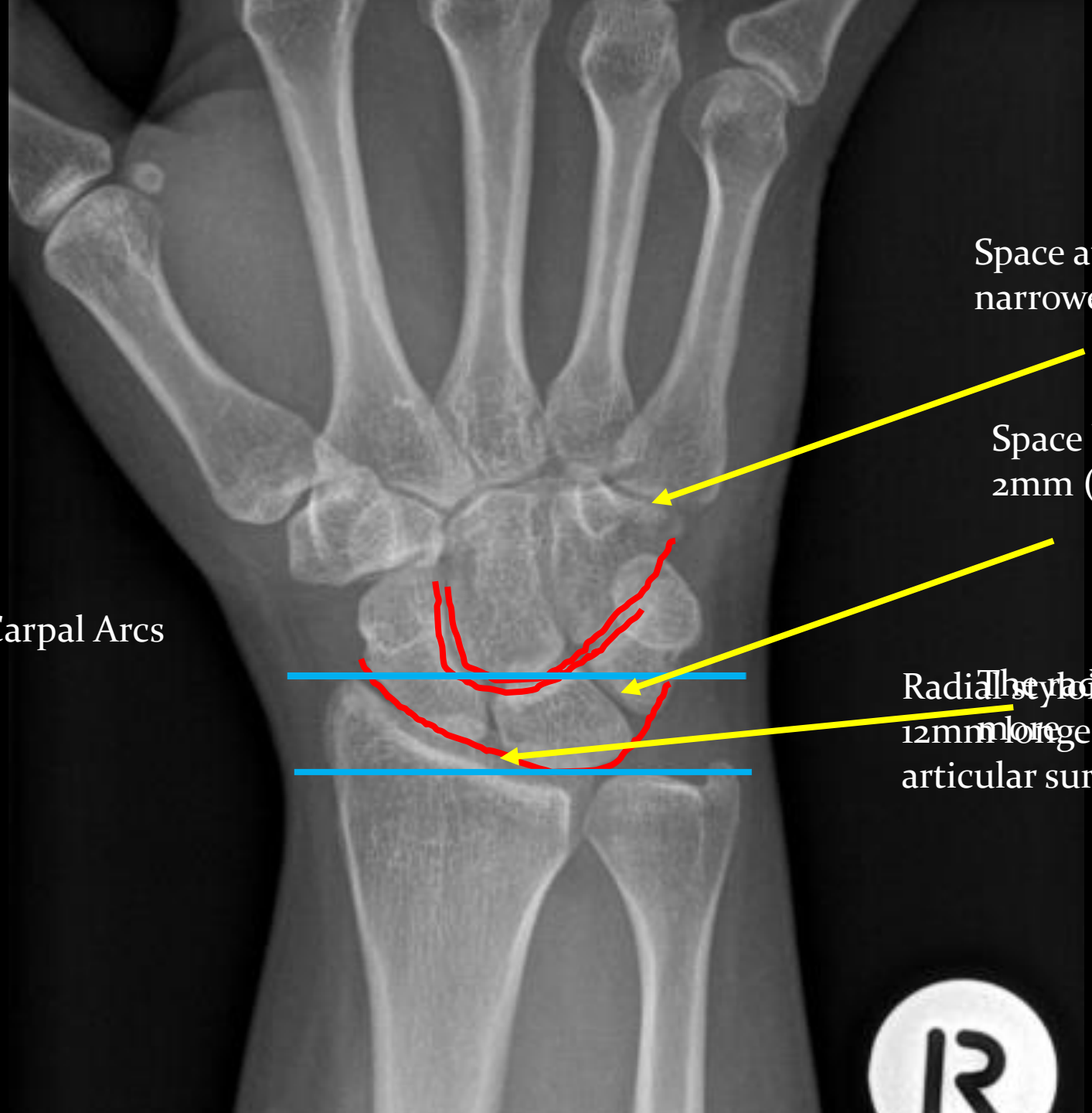

Space at CMC jts should be slightly narrower

Space between carpals should be 2mm (or less)

Carpal Arcs

Radial styloid should be about 9-12mm longer than the ulnar articular surface

The radiocarpal space is slightly more

PA Oblique

Positioning and Alignment For Image

- Pt sitting on chair at edge of table
- Elbow bent to 90, full pronation
- Wrist is externally rotated (supinated) 40 degrees

Checking the Orientation of the Film

- The ulnar head and distal radius are slightly superimposed
- The proximal metacarpals 3-5 are partly superimposed

Lateral

Positioning and Alignment For Image

- Pt sitting on chair at edge of table
- Elbow bent to 90, forearm in mid prone with thumb up
- Fingers comfortably flexed

Checking the Orientation of the Film

- Ulnar head should be superimposed over the distal radius
- Proximal 2nd through 5th metacarpals should be aligned and superimposed

Lateral

There is a normal volar tilt of the distal radius of 10-15 degrees

Lateral

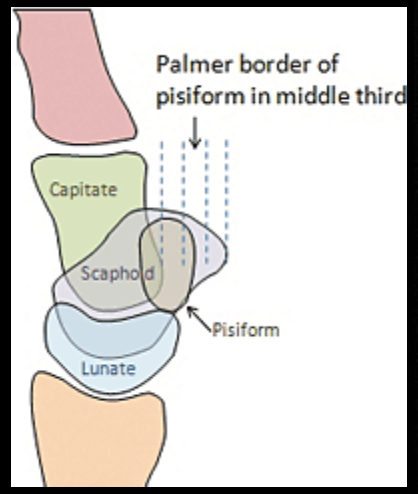

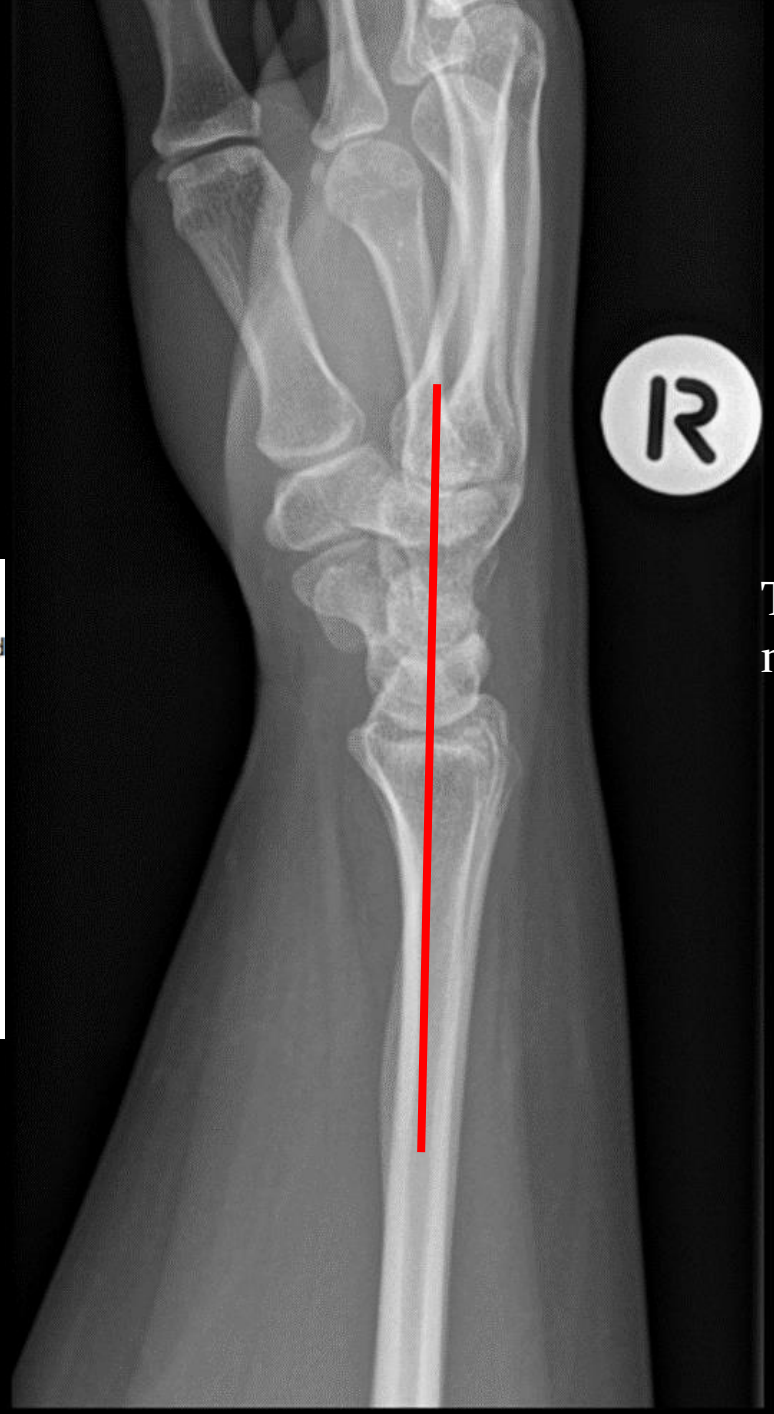

The radius, lunate, capitate and 3rd metacarpal base should all line up

Lateral

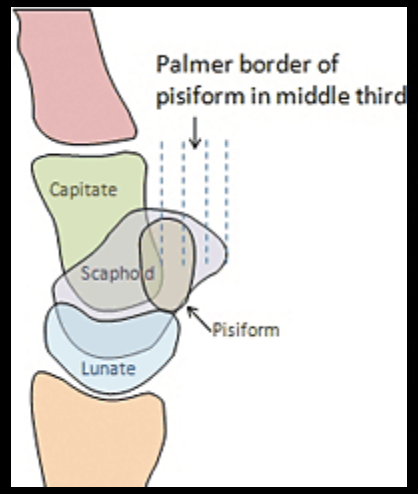

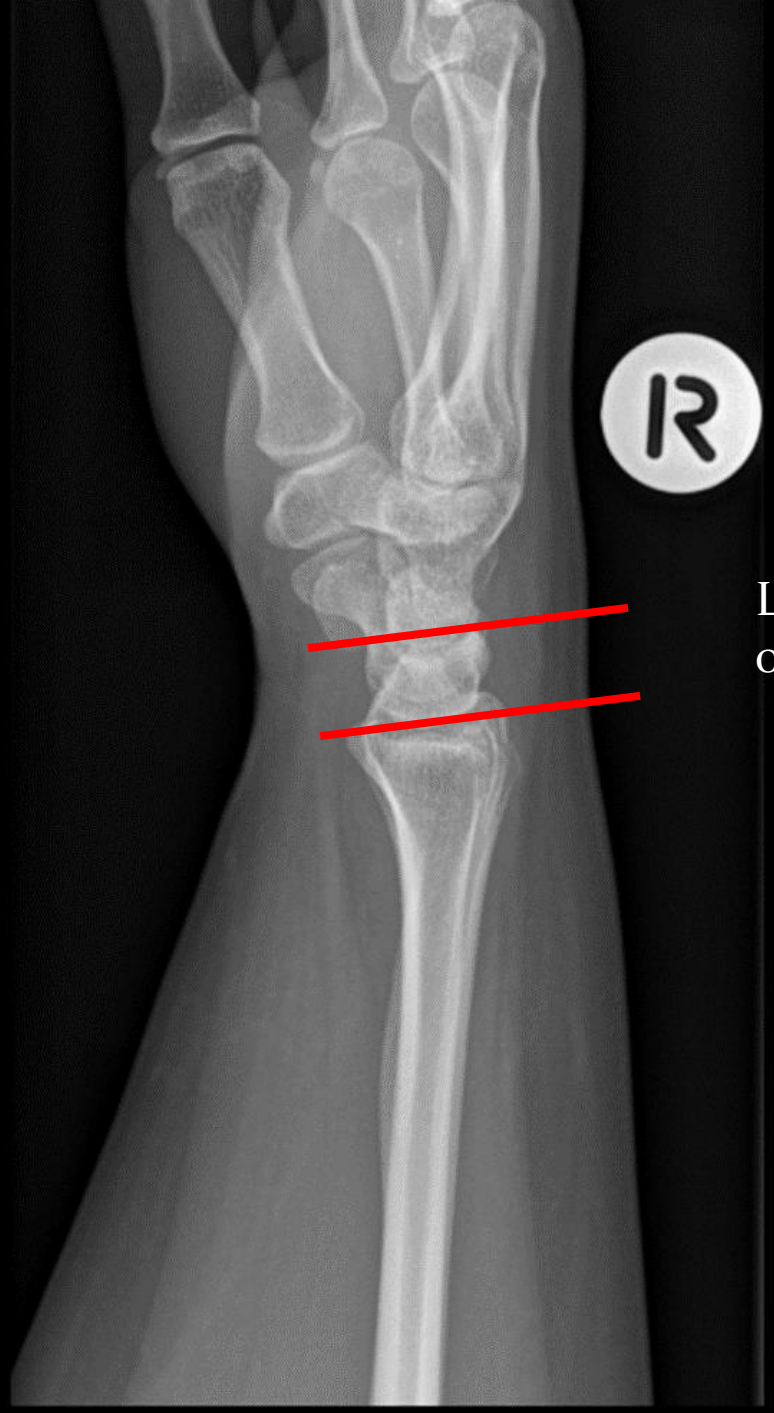

Lunate should follow the volar tilt of the radius

Pronator Fat Pad

- Appearance about 90% of time on normal x-rays
- Displacement, anterior bowing or obliteration of the fat plane in setting of trauma may indicate a distal radius or ulna fracture.
- Wide ranging sensitivity for fracture ranging from 26 to 98% and thus a negative pronator quadratus sign does not exclude fracture

Normal

Bowed

Displaced

PA Scaphoid Ulnar Deviation

Positioning and Alignment For Image

- Pt sitting on chair at edge of table
- Elbow bent to 90, pronation
- Upper arm on table with volar forearm and wrist flat on plate
- Hand elevated on sponge with wrist in ulnar deviation)

Checking the Orientation of the Film

- Minimal, if any superimposition of the distal scaphoid
- Minimal, if any superimposition of the superior radioulnar joint

Scaphoid Fat Pad

- "Scaphoid fat pad" sign
  - Anatomically found to actually be the common tendon sheath of the EPB and APL
  - Fractures of scaphoid, radial styloid or first metacarpal often result in displacement or obliteration of this stripe
  - Unreliable

PA Scaphoid Clenched Fist

Checking the Orientation of the Film

- Minimal, if any superimposition of the distal scaphoid
- Minimal, if any superimposition of the superior radioulnar joint

Positioning and Alignment For Image

- Pt sitting on chair at edge of table
- Elbow bent to 90, pronation
- Upper arm on table with volar forearm and wrist flat on plate
- Make fist with ulnar deviation

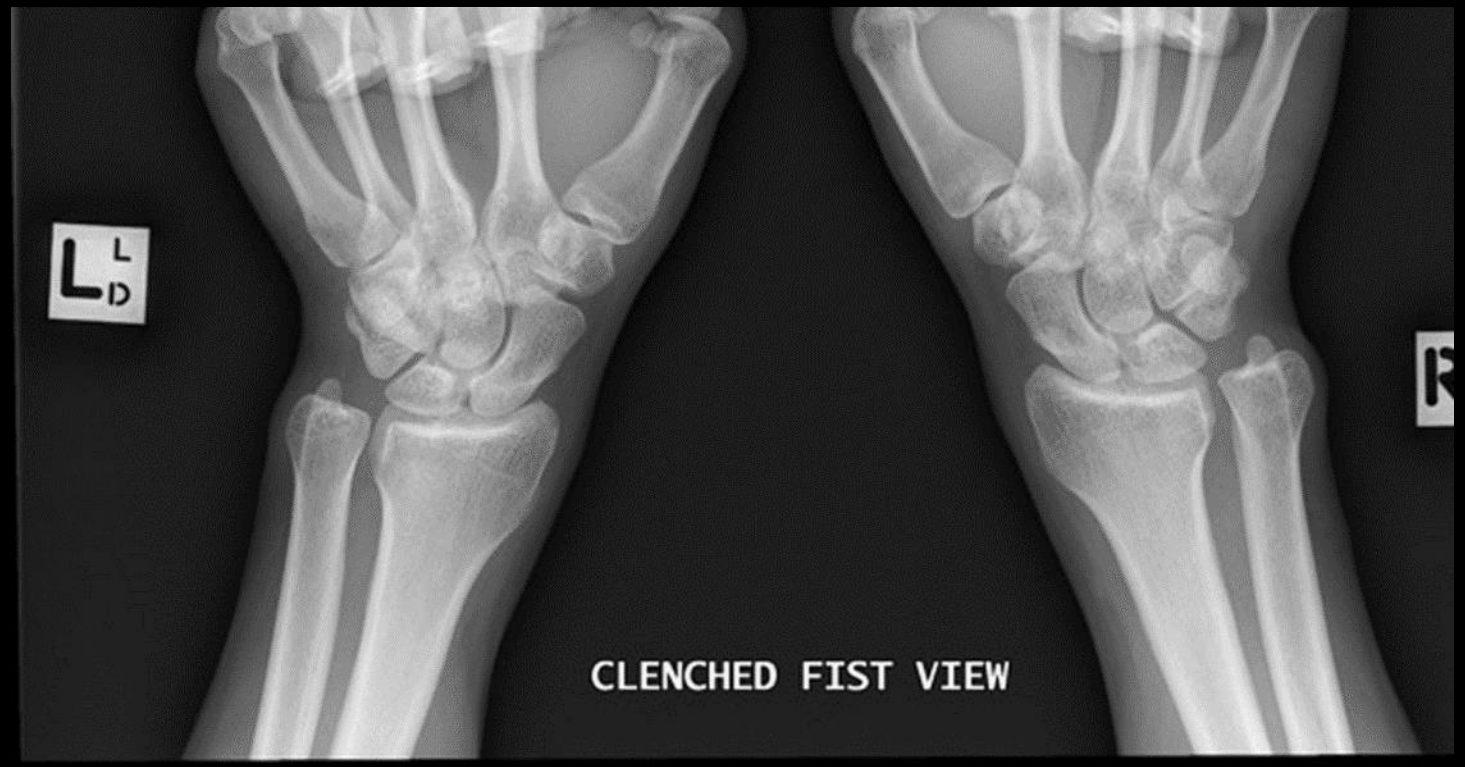

SCAPHOID FRACTURES

WELCOME

SCAPHOID FRACTURES

Overview

- Scaphoid fractures are a diagnostic challenge

- Scaphoid is the most commonly injured carpal bone
  - 82-89% of all carpal fractures (Rhemrev et al, 2011)
  - 2% of all fractures (Larsen et al, as cited by Cheung et al, 2006)

Overview

- Snowboarding wrist fractures (Idzikowski et al, 2000):
  - Scaphoid 4%
  - Distal radius and ulna 95%

http://www.youtube.com/watch?v=6wT77T7hkc

Overview

- Uncommon in very young and very old due to the relative weakness of the distal radius in these groups

(Guttierrez as cited by Phillips et al, 2004).

Overview

- Untreated fractures of the scaphoid are significantly more likely to develop:
  - delayed union
  - non-union
  - avascular necrosis
  - decreased grip strength and range of motion
  - collapse and / or osteoarthritis of the radiocarpal joint

(Greene as cited by Phillips et al, 2004).

http://www.radiologytutorials.com/getimage.cgi?i=bfder/2/288&t=1409

Scapholunate Advanced Collapse

SCAPHOID FRACTURES

ANATOMY

Anatomy

- 80% of the surface is covered with articular cartilage, leaving little area for vascular supply

(Rhemrev et al, 2011)

Anatomy

- Scaphoid articulates with the distal radius, lunate, trapezium, trapezoid and capitate.

Radial Collateral Ligament

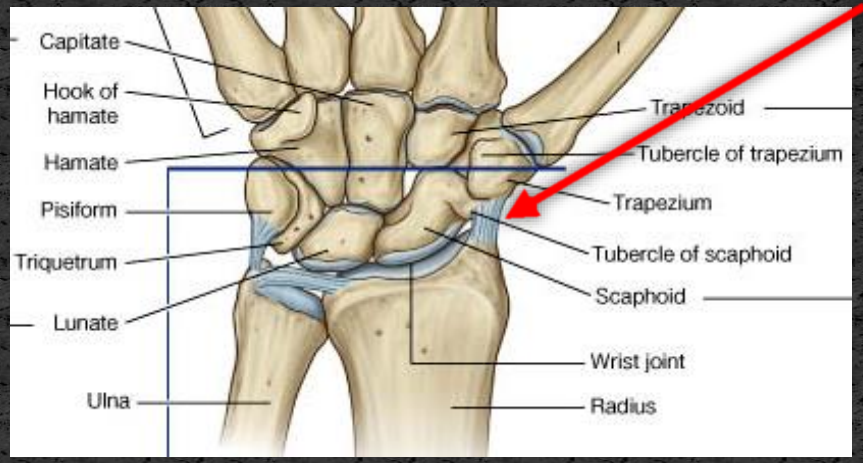

http://1.bp.blogspot.com/-90UiQkNNEV0/TiAGkRIc-CI/AAAAAAAAAI0/GFRuNPi6s0s/s1600/carpal+bones.jpg

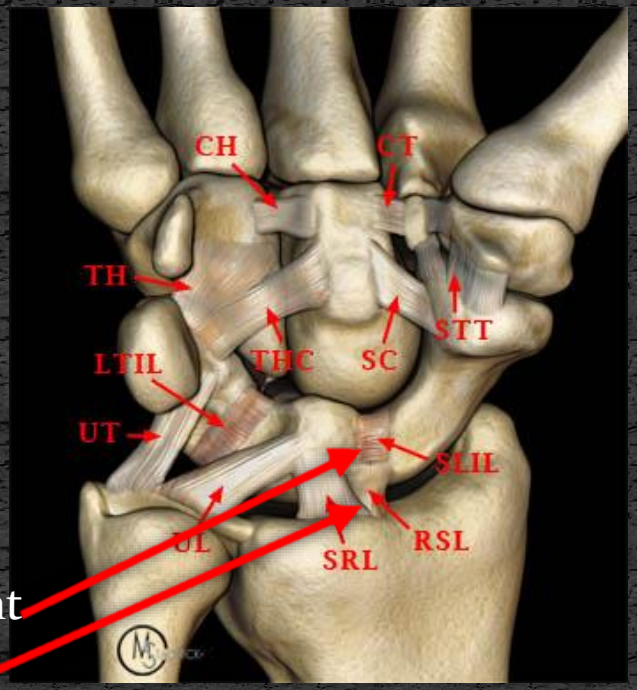

Scapholunate Interosseus Ligament

Radioscaphoid Ligament

http://www.radsource.us/_images/0612_10.jpg

Anatomy

- Radial artery sends retrograde branches to supply the scaphoid with the proximal portion having no direct blood supply

(Phillips et al, 2004; Gelberman as cited by Rhemrev, 2011)

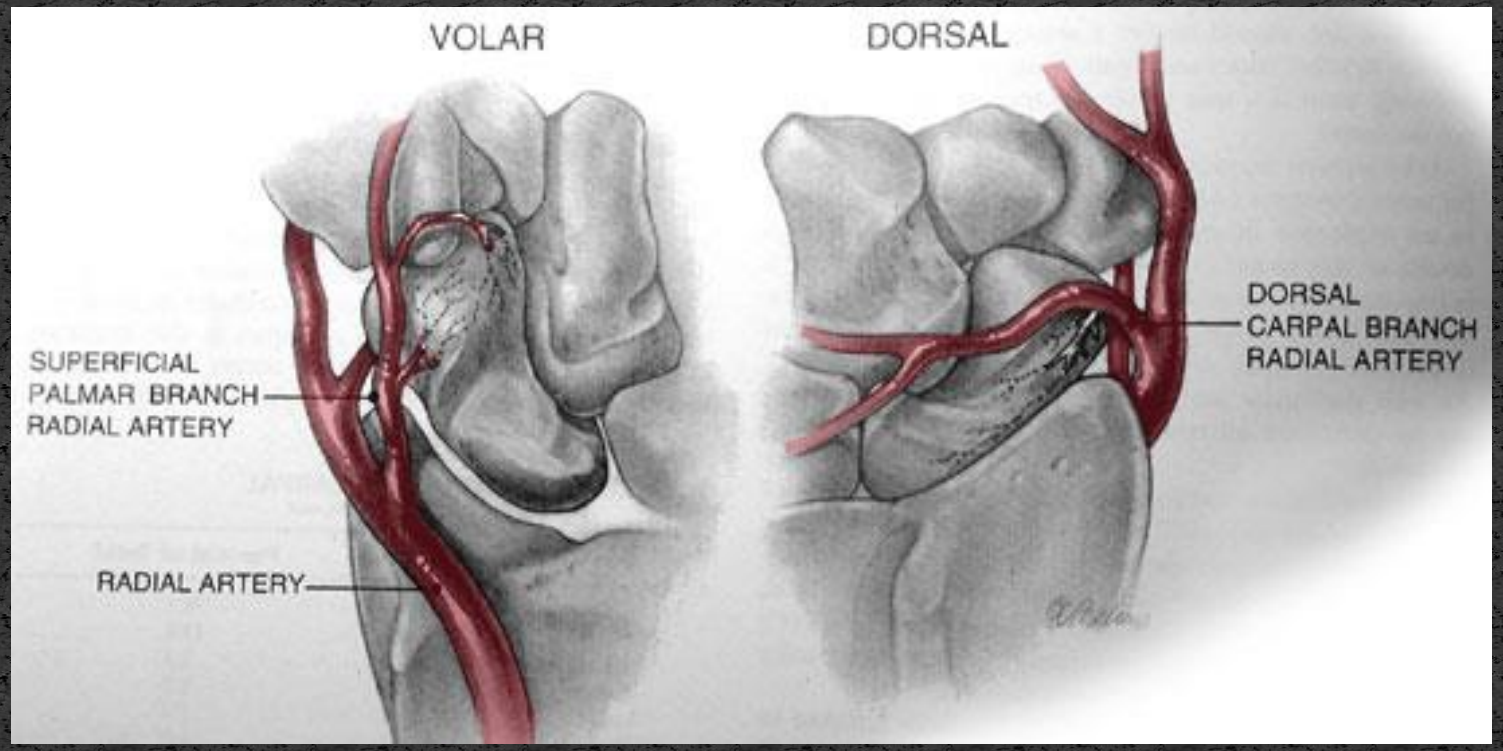

http://morphopedics.wdfiles.com/local--files/scaphoid-fractures/BloodSupply.jpg

Anatomy

- Resulting poor blood supply often results in non-union to proximal scaphoid fractures

(Phillips et al, 2004; Gelberman as cited by Rhemrev 2011)

http://www.wheelessonline.com/images/11/scphn1.jpg

Anatomy

- The close packed position of the wrist is full extension

(Norkin and Levangie 5nd ed., 2010)

- In full extension, the proximal pole of the scaphoid becomes compressed between the radius and the capitate

(Weber and Chao, 1978 as cited by Farnell and Dickson, 2010)

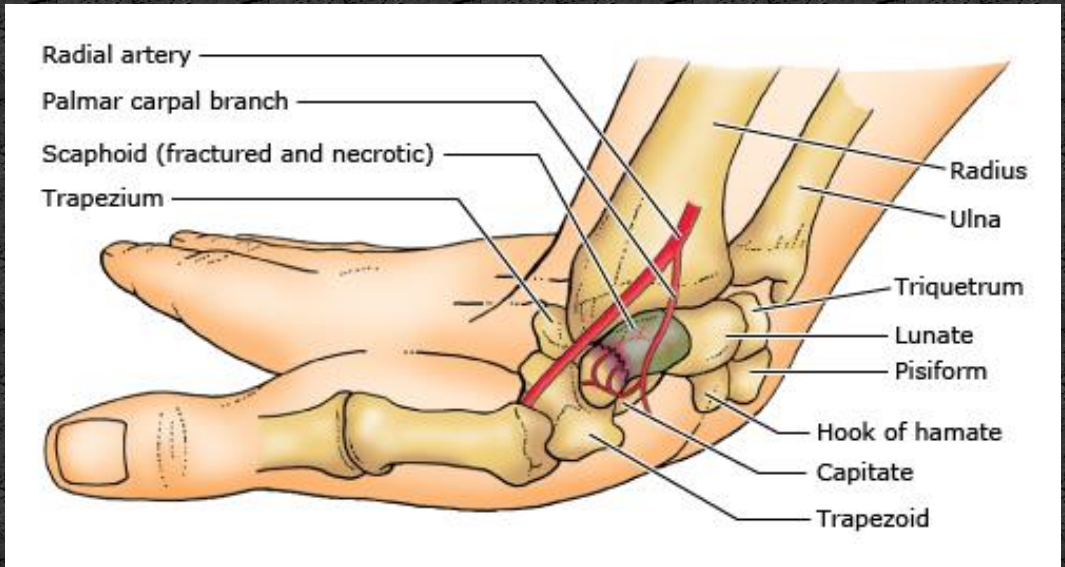

http://www.uptodate.com/contents/image?imageKey=EM%2F50525&topicKey=EM%2F197&rank=1%7E43&source=see_link&search=scaphoid&utdPopup=true

SCAPHOID FRACTURES

MECHANISM AND CLASSIFICATION

Mechanism

- Most common mechanism is FOOSH

(Hove, 1999 as cited by Stevenson et al, 2011).

http://www.youtube.com/watch?v=BjLiGqC_YsI

Mechanism

Mechanism	Percentage
Fall on outstretched hand	59
Road traffic accident	12
Direct blow	7
Forced hyperextension	5
Starting handle kickback	3
Fall on dorsum of hand	3
Unclassifiable	11

(Clay et al, 1991)

Classification

Fracture Type	Incidence	Union rate
Waist	80%[1]	Undisplaced:90-98%[2,3,4] Displaced: 50-69%[3,4]
Proximal third	15%[1]	40-69%%[2,3]
Distal third	4%[1]	100%[3]
Distal tubercle	1%[1]	100%[3]

([1]Eiff et al, 1998; [2]Clay et al, 1991; [3] Farnell and Dickson, 2010; [4] Geoghegan et al, 2009)

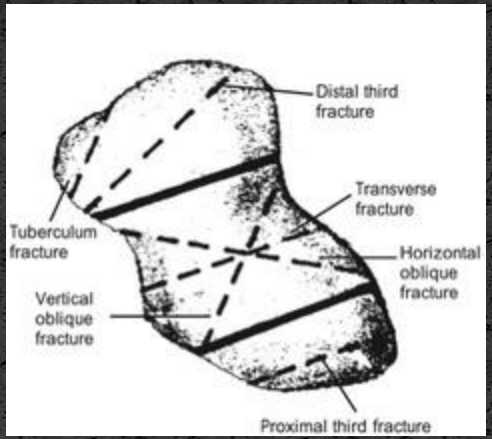

http://morphopedics.wdfiles.com/local--resized-images/scaphoid-fractures/Types.jpg/small.jpg

SCAPHOID FRACTURES

ASSESSMENT

Assessment

Assessment

- Comprehensive Sx / Ox Assessment
- "Snuff Box Tenderness"
  - Traditionally the major assessment used to assess for scaphoid injury

BUT IS THAT ENOUGH??

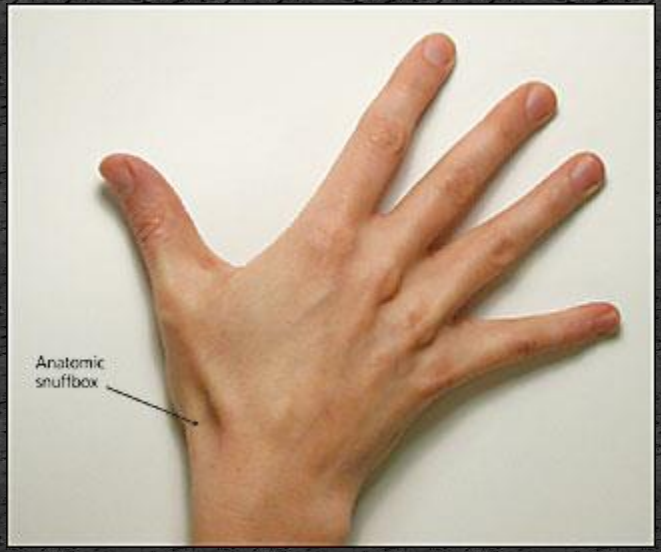

http://www.pearsoncycles.co.uk/blog/images/snuff.jpg

Assessment

- Clinical tests

Signs	Sensitivity	Specificity
Snuff Box Tenderness[1,2]	90-100%	9-40%
Scaphoid Tubercle Tenderness[1,2]	87%-100%	30-57%
Pain on Axial Compression Through the First Metacarpal[2]	100%	48%
Two or More of First Three Tests[2]	100%	54%
First Three Tests Combined[2]	100%	75%

[1]Freeland, 1989 [2]Parvizi et al, 1998

IMAGING

Imaging

- Due to irregular shape and multiple articulations, imperative that appropriate views are taken
- Standard wrist PA and lateral x-rays miss 10-20% of these fractures

(Perron et al, 2001)

- Dedicated scaphoid views are recommended

(Cheung et al, 2006)

SCAPHOID FRACTURES

Imaging

- 7-20% of scaphoid fractures may not be visible on initial plain radiographs, even with dedicated views

(Ring, 2008; Hunter as cited by Stevenson et al, 2011; Gaebler as cited by Beeres et al, 2006)

- Non union rate increases to 30% if inadequately immobilised

(Furunes, Langhoff, Sjolin all cited by Rhemrev et al, 2011)

Initial Management

- In Australasia, typical management for a suspected scaphoid fracture is a scaphoid splint or cast and:
  - Reviewed clinically in 7-14 days (approx. 70%) and referred for repeat radiographs if clinically indicated

    OR

  - Early secondary imaging such as CT-Scan, bone scintigraphy or MRI

(Kelly, 2010)

SCAPHOID FRACTURES

Review

- Stevenson et al (2011) found that in a study of 84 patients with normal initial x-rays but suspicion of scaphoid fracture:
  - 7% actually had scaphoid #s (other studies = 20%)
  - 23% had other #s
    - 18% of other carpals
    - 5% of distal radius

Review

- No gold standard to compare to in research
- Most studies use plain films at 6 weeks as reference point, BUT up to 7% of #s NOT visible on plain films at 6/52

(Mallee et al, 2011; Yin et al, 2012)

Review

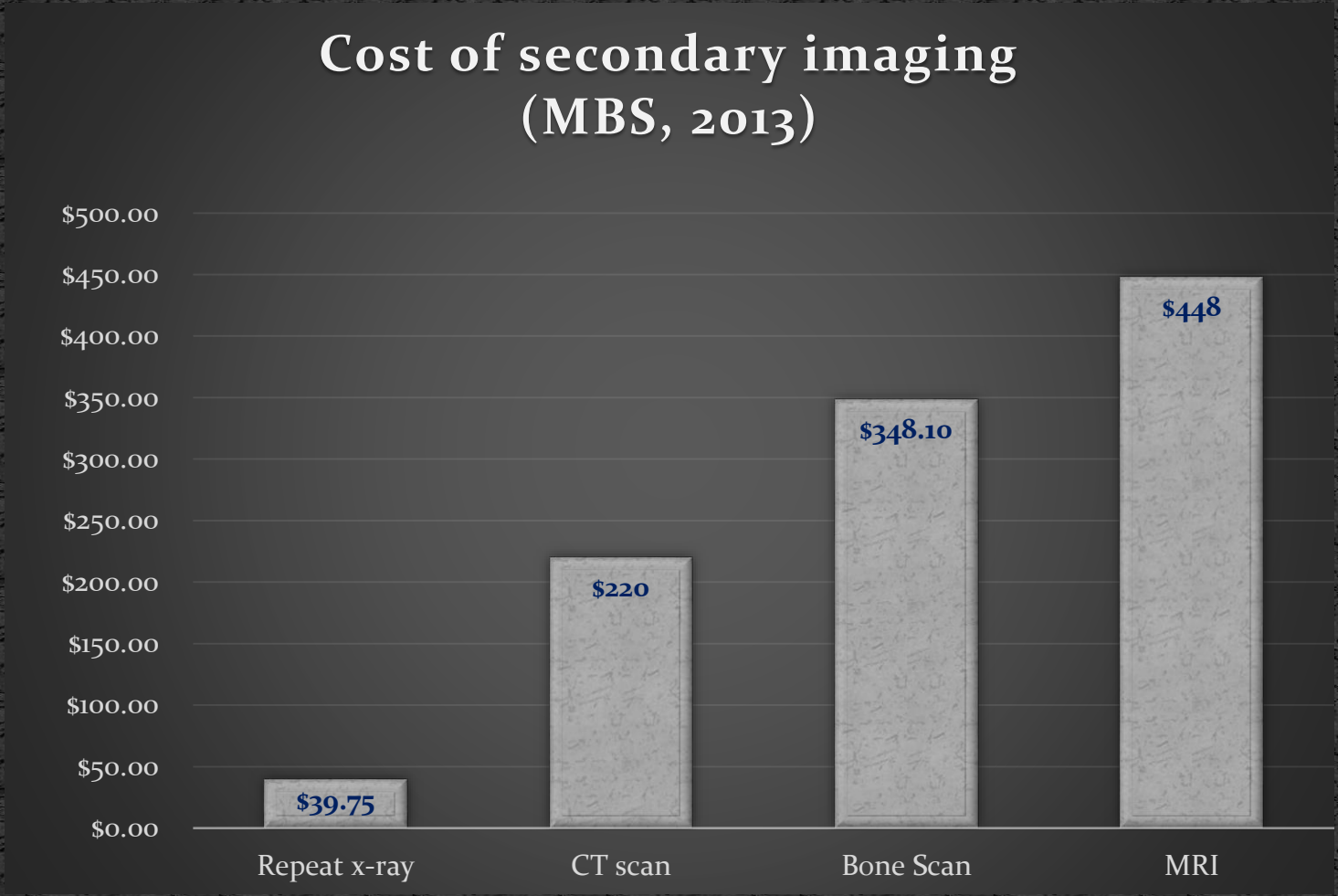

MRI requires specialist referral for MBS rebate (unless patient under 16), otherwise all other modalities can be referred by a GP.

Review

Modality	Sensitivity	Specificity	Comments
Followup Radiographs	91.1%	99.8%	
CT Scan	85.2%	99.5%	Difficulty in distinguishing between vascular channels / trabecular patterns and #
Bone Scintigraphy	97.8%	93.5%	• Invasive procedure • Takes 2-3 hours • Difficult distinguishing between #, bone bruise, soft tissue injury and adjacent joint / bony injury
Magnetic Resonance Imaging	97.7%	99.8%	Bone marrow oedema - ? Bone bruising or # ??

(Yin et al, 2012)

SCAPHOID FRACTURES

Management

- Unsure when and why scaphoid cast became correct treatment

(Clay et al, 1991)

- To immobilise the thumb or not to immobilise the thumb – that is the question!

Management

vs

- Round 1 (Cadaver model)
  - Wrist immobilisation crucial (no cast = # moved)
  - Inclusion of the thumb made NO difference
  - BUT 100% non-union

(Schramm et al, 2008)

- Round 2
  - Clay et al (1991) found NO difference in union rate or function

- Round 3
  - Significant difference favouring immobilisation the wrist EXCLUDING the thumb (? why)
  - Well moulded and fitting cast may be more important than whether the thumb is included or not

(Buijze et al, 2014)

- Does the position of the wrist affect healing??

SCAPHOID FRACTURES

Cast Duration

- Most scaphoid fractures are managed in a cast for 6-12 weeks
- Some ready at 4 weeks
  - Geoghegan et al (2009) found that 86% of patients had radiographic union on CT at 4 weeks
  - Of those patients who then had their casts removed, there were no adverse events
  - Remaining patients took up to 4 weeks to unite
- Most united within 12 weeks
  - All patients with undisplaced fractures of the waist were united within 12 weeks
  - Only 67% of those with ***displaced*** fractures were united

(Bhat et al 2004, as cited by Geoghegan et al, 2009)

- Cast time = until is it healed!
  - Evidence of callus bridging on imaging
  - Absence of fracture site tenderness

(McRae and Esser 5th ed., 2008)

SCAPHOID FRACTURES

CASE STUDIES

Case Studies

- 13 year old boy
- FOOSH from pushbike

- X-rays initially within 12 hours = NAD
- Managed in scaphoid cast
- Follow-up x-rays at 16 days = NAD but still suspicious of further injury
- MRI taken at 4 weeks

Case Studies

Cortical bone is black.

PD

Case Studies

Oedema is bright white.

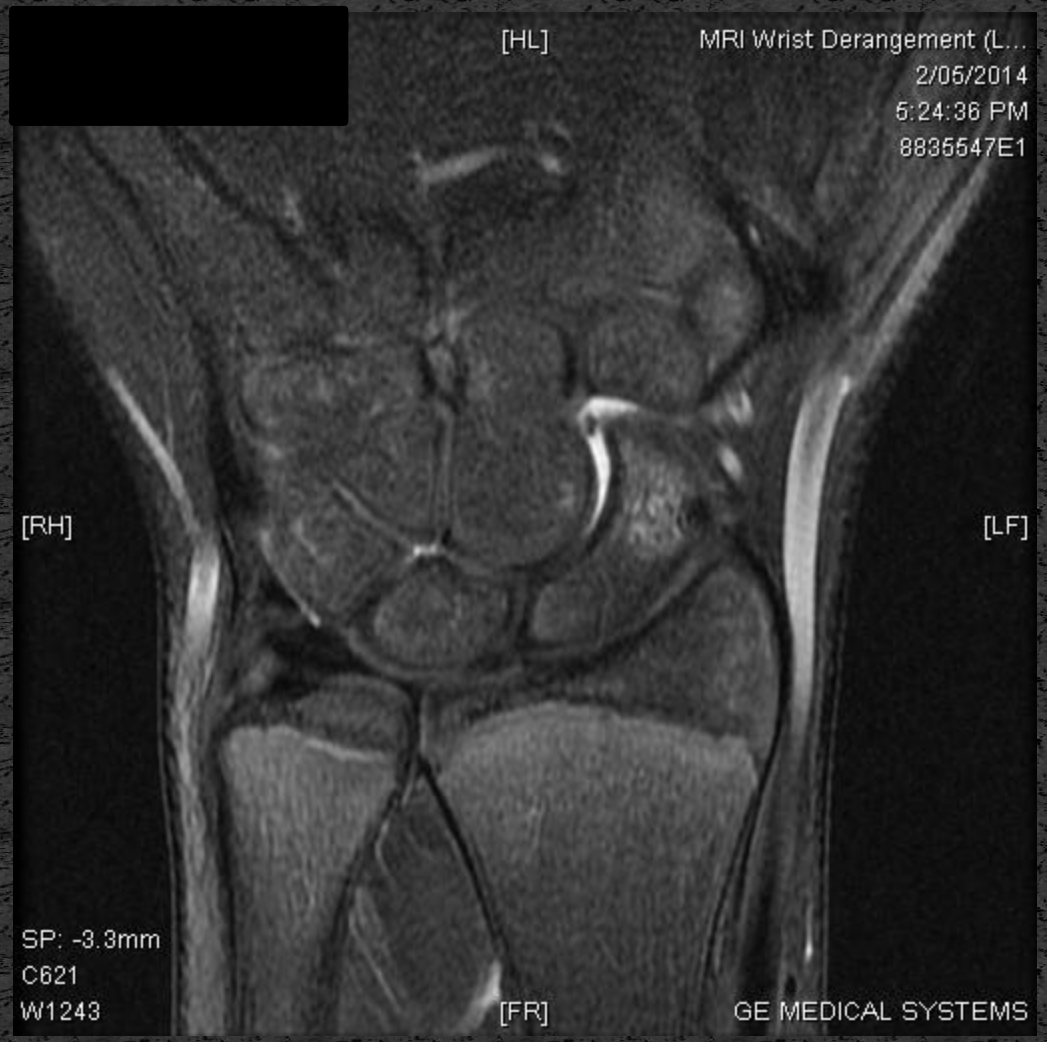

T2 Fat Sat

Case Studies

Oedema is bright white.

T2 Fat Sat

Case Studies

- 68 year old man had fall injuring wrist 4/12 ago
- Saw GP – had x-rays = NAD
- Pt continued to have wrist pain, clicking
- Making the bed the night before ED presentation (4/12 later) and wrist clicked again
- Had persisting snuff box tenderness, pain on axial compression, loss of 50% of extension range and power

Case Studies

TEST TIME

Scapholunate Dissociation with Radial Fracture

Lunate Dislocation

Perilunate Dislocation

Smiths Fracture

Barton's Fracture

Buckle Fracture

Greenstick Fracture


L
L
L
Scaphoid Fracture

Ununited Scaphoid Fracture

Normal

Intra-articular Fracture of the Distal Radius

Reduced Intra-articular Fracture of the Distal Radius

QUESTIONS

THANKS

Useful References

http://www.medecine.uottawa.ca/radiology/assets/documents/msk_imaging/articles/Radiographic%20Evaluation%200f%20the%20Wrist%20%E2%80%93%20A%20Vanishing%20Art.pdf